



Received: September 26, 2025
Revised: December 3, 2025
Accepted: December 9, 2025

Corresponding Author:
Peraya Puapichartdumrong,
Department of Restorative
Dentistry, Faculty of Dentistry,
Naresuan University, Phitsanulok
65000, Thailand
E-mail: perayap@nu.ac.th

Regenerative Endodontic Therapy in a Necrotic Immature Tooth with Chronic Apical Abscess with Apical Placement of Calcium Hydroxide: A Clinical Case Report

Wittaya Saengmueankwan¹, Ruedee Sakulratchata², Kasidid Ruksakiet³,
Peraya Puapichartdumrong³

¹Wangthong Hospital, Thailand

²Department of Preventive Dentistry, Faculty of Dentistry, Naresuan University, Thailand

³Department of Restorative Dentistry, Faculty of Dentistry, Naresuan University, Thailand

Abstract

Managing necrotic immature teeth is complex due to thin root walls and open apices. Regenerative endodontics has emerged to overcome these limitations. These biologically based approaches aim to restore pulp vitality and promote further root development by using dental stem cells and revascularization. A female patient aged 9 years and 4 months diagnosed with dens evaginatus, necrotic pulp, and a chronic apical abscess in an immature mandibular premolar underwent treatment with regenerative endodontic procedures (REPs). Calcium hydroxide (Ca(OH)₂) medication was applied to the apical region of the root canal. Over a 22-month follow-up period, the tooth remained asymptomatic, and radiographic assessments revealed periapical healing, apical closure, root lengthening, and dentinal wall thickening. The favorable outcomes observed suggest that apical placement of Ca(OH)₂ during REPs may be a promising approach for managing immature teeth with pulp necrosis and chronic apical abscess, supporting both disinfection and root maturation.

Keywords: calcium hydroxide, case report, immature tooth, regenerative endodontics

Introduction

Pulp necrosis in immature permanent teeth is most commonly associated with dental trauma and caries.⁽¹⁾ Developmental anomalies, particularly dens evaginatus (DE), may also contribute. DE is characterized by an extra cusp, often containing pulp tissue, on the occlusal or lingual surfaces of premolars and incisors⁽²⁾ and has a reported prevalence of 0.5%-4.3% in Asian populations.⁽³⁾ Fracture or attrition of the DE cusp may result in pulp exposure and subsequent necrosis, especially in teeth with incomplete root formation.⁽²⁾ Early diagnosis and preventive intervention are therefore essential to minimize pulpal and periapical complications.⁽⁴⁾

Endodontic treatment of immature permanent teeth exhibiting pulp necrosis poses significant clinical challenges due to their structurally compromised root canal systems. Complications often include thin dentinal walls that are susceptible to fracture, open apices that impede conventional obturation, and inadequate root length and thickness to withstand functional forces.⁽⁵⁾ To overcome these challenges, regenerative endodontic procedures (REPs) have been introduced as biologically informed approaches that aim to restore pulp vitality and promote continued root development through revascularization and the recruitment of dental stem cells.⁽⁶⁾

Effective disinfection of the root canal system is a crucial factor for the success of REPs.⁽⁶⁾ Intracanal medications, such as antibiotic pastes and calcium hydroxide (Ca(OH)₂) have been commonly used to achieve microbial control.⁽⁷⁾ Evidence suggests that the type and placement of these drugs may influence regeneration outcomes. While Ca(OH)₂ has been reported to promote apical closure, antibiotic pastes have increasingly been associated with enhanced root wall thickening.⁽⁸⁾ The coronal placement of Ca(OH)₂ has been proposed due to its reduced cytotoxicity to apical stem cells,⁽⁹⁾ with one study further highlighting its association with increased dentinal wall thickness.⁽⁷⁾ This approach has been supported by several reports demonstrating favorable clinical outcomes.⁽¹⁰⁻¹⁴⁾ However, contrasting evidence has also suggested that Ca(OH)₂ placed in the apical portion of the canal effectively stimulates root wall thickening.^(15,16) The objective of this case report was to provide additional evidence that apical placement of Ca(OH)₂ within the root canal can contribute to favorable root development, including increased dentinal wall thickness, in a necrotic

immature tooth with chronic apical abscess.

Case Report

A female patient aged 9 years and 4 months was referred to the University Dental Hospital. The chief complaint was a sinus tract exhibiting purulent discharge on the buccal attached gingiva associated with the mandibular right second premolar. The patient's parent reported that the tooth initially presented with a prominent occlusal tubercle that fractured and remained untreated. Following the fracture, the patient experienced recurrent buccal abscesses, with intermittent drainage through the gingival tissues. Two months prior to referral, symptomatic treatment was administered for one week at a private dental clinic, comprising antibiotics and analgesics.

The patient had no relevant medical history and was classified as American Society Anesthesiologists (ASA) Class I. Extraoral examination confirmed a lack of facial swelling or asymmetry. Clinical intraoral examination revealed that the mandibular right second premolar presented with a small, deep occlusal cavity revealing of a fractured tubercle, with no evidence of dental caries. A sinus tract opening was observed on the buccal gingiva between the mandibular right second premolar and first molar. Periodontal probing depths were within normal limits, and the tooth showed grade I mobility, without tenderness to palpation or percussion. Pulp sensibility tests elicited no response to cold or electric pulp testing (EPT).

Digital periapical radiographs were obtained and scanned using a VistaScan imaging system (Dürr Dental, Bietigheim-Bissingen, Germany). The image showed a Cvek's stage 3 root⁽¹⁷⁾ with thin walls (Figure 1A). Periapical radiolucency was measured using VixWin Platinum software (Gendex Dental Systems, Hatfield, PA, USA). Gutta-percha tracing confirmed the mandibular second premolar as the origin of infection (Figure 1B). The clinical diagnosis was DE, pulp necrosis, and a chronic apical abscess. Informed consent was obtained following a comprehensive discussion of available treatment alternatives.

The treatment protocol followed clinical considerations for REPs guided by the American Association of Endodontists (AAE).⁽¹⁸⁾ A right inferior alveolar nerve block was administered using 2% lidocaine with 1:100,000 epinephrine (Medicaine, Huons Co. Ltd., Seongnam-

si, Korea). Following rubber dam isolation, an access cavity was prepared. The tooth length was determined using an electronic apex locator (Root ZX, J. Morita, Kyoto, Japan) and confirmed radiographically with a size 25 K-file (Kerr Dental, Orange, CA, USA) as 17 mm. The necrotic pulp tissue removal and root canal disinfection were performed using gentle irrigation with 20 mL 2.5% sodium hypochlorite (NaOCl), normal saline solution, and 17% ethylenediaminetetraacetic acid (EDTA) for 5 minutes each, without mechanical instrumentation. Ca(OH)₂ was mixed with 2% lidocaine containing 1:100,000 epinephrine (Medicaine, Huons Co. Ltd., Seongnam-si, Korea) to a creamy consistency. The resulting paste was applied to the apical region of the root canal, approximately 2 mm short of the tooth length, using a lentulo spiral. A double seal was applied using Cavit (Triune Med Tec, Cambridgeshire, UK) and IRM (Dentonics, Monroe, NC, USA).

After 2 months, the patient remained asymptomatic, with no signs of pain or swelling, and complete resolution of the previously observed sinus tract. Clinical examination showed normal mobility, with no sensitivity to palpation or percussion. Following administration of an inferior alveolar nerve block with 3% mepivacaine without vasoconstrictor (Septodont, New Castle, DE, USA), the canal was re-accessed and irrigated with 17% EDTA. Bleeding was induced using a size 25 K-file to a depth of 19 mm, and controlled at the level of the cemento-enamel junction (CEJ). After approximately 15 minutes, a stable blood clot was formed. A resorbable collagen matrix (CollaPlug; Zimmer Dental, Carlsbad, CA, USA) was placed over the clot, followed by a 4-mm layer of Biodentine (Septodont, Saint-Maur-des-Fossés, France) to serve as a coronal barrier. The access cavity was then restored using a resin-modified glass ionomer (Fuji II LC; GC Corp., Tokyo, Japan) and composite resin (Estelite; Tokuyama Dental, Tokyo, Japan) (Figure 1C).

At 6-, 10-, and 22-month follow-up visits following the REPs, the patient remained asymptomatic. Despite consistently negative responses to pulp sensibility testing (cold and EPT), radiographic evaluation demonstrated periapical healing and continued root development, characterized by increased root length, dentinal wall thickening, and apical closure (Figures 1D-1F). Radiopacity within the canal space was observed at 6 months, and further increased by 10 and 22 months, indicating

continued calcific tissue formation. A secondary carious lesion beneath the previous restoration was identified and managed. Oral hygiene instructions were reinforced, and other teeth presenting with DE were examined and managed appropriately.

To assess changes in root wall thickness and root length, a modified method based on a previously reported protocol was employed.⁽⁷⁾ Pre- and post-operative radiographs were analyzed using ImageJ (version 1.41; National Institutes of Health, Bethesda, MD, USA). Horizontal reference lines were established at the CEJ and at positions 3, 6, and 9 mm apical to the CEJ to represent the coronal, middle, and apical levels of the root, respectively. Root and canal widths were measured at each level, and root wall thickness was calculated by subtracting the canal width from the corresponding root width. Root length was measured from the CEJ to the apex. Measurement outcomes are summarized in Table 1 and illustrated in Figure 2.

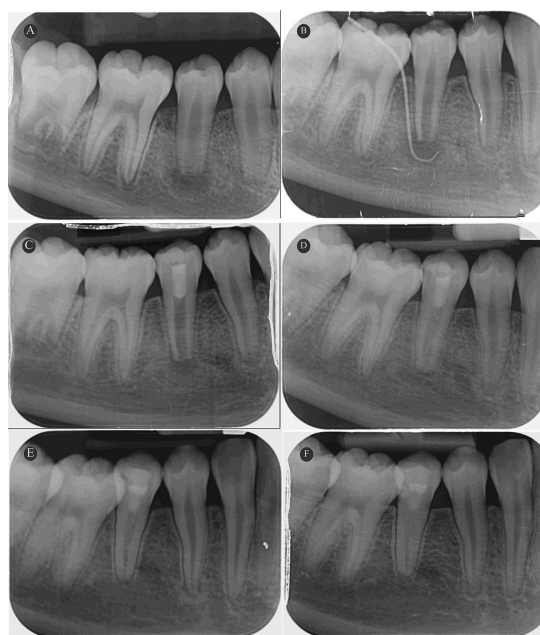


Figure 1: Periapical radiographs of the mandibular right second premolar during the regenerative endodontic treatment: (A) a pre-operative periapical radiograph showed an immature root with a periapical lesion; (B) a sinus tracing radiograph; (C) a radiograph post-induced bleeding into the root canal and coronal restoration showed a reduction in the size of the periapical lesion; (D) a 6-month follow-up radiograph showed continued root development and a widening of the periodontal ligament space; (E) a 10-month follow-up radiograph showed continued root development with radiopacity in the root canal and a widening of the periodontal ligament space; and (F) a 22-month follow-up radiograph showed continued root development with a closed apex and normal periapical tissue.

Discussion

The treatment success of REPs is influenced by multiple factors, including stem cell viability, effective canal disinfection, patient age, and root morphology.^(6,19,20) Favorable outcomes have been associated with patients aged 9-13 years and apical diameters >1.0

mm, both of which were true in the present case.⁽²⁰⁾ A wide apex may contribute to tissue preservation and stem cell migration, facilitating successful regeneration.⁽²¹⁾ This case report was evaluated using the AAE's clinical and radiographic criteria⁽¹⁸⁾, which define success primarily by resolution of clinical signs and symptoms and radiographic evidence of periapical healing, secondarily by increased root length and dentinal wall thickness, and finally by restoration of pulp vitality.

Determining an accurate working length in immature teeth with open apices remains a considerable clinical challenge, particularly in REPs, where precise canal disinfection and intracanal medication placement must be achieved without irritating the apical stem cells. Current expert consensus recommends determining the working length using a radiograph with the endodontic file positioned 1 mm short of the radiographic apex on REPs, without specifying the file size.⁽⁶⁾ Electronic apex locators have been used to assess the working length with increased predictability. However, their reliability was reduced when an apical foramen diameter exceeded 0.6 mm because of a reduced effective contact between the file and apical canal walls.⁽²²⁾ In this case report, the electronic apex locator was used as an adjunctive tool⁽²³⁾, and the definitive working length was verified radiographically.

Among multiple factors, persistent microbial infection is considered a primary contributor to the clinical signs and symptoms of apical periodontitis.⁽¹⁹⁾ Thorough disinfection of the root canal system is therefore an essen-

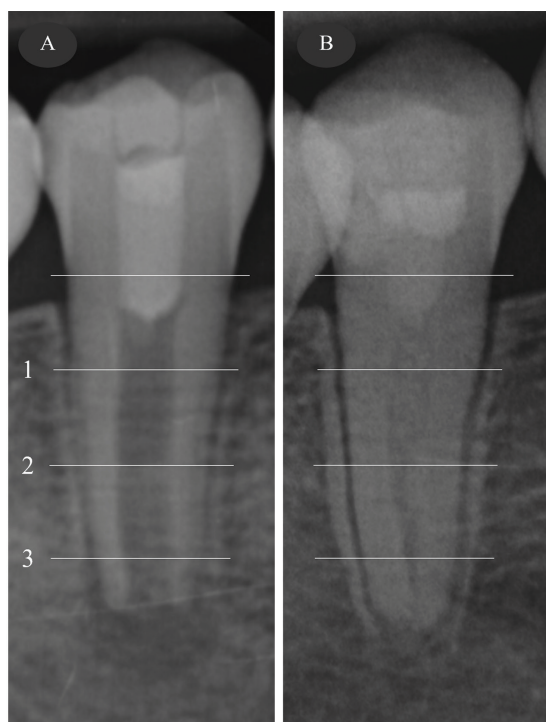

Figure 2: Images showed the three horizontal reference lines for the root and canal width measurements using ImageJ software: (A) a radiograph post-induced bleeding and (B) a 22-month follow-up radiograph. (1=coronal, 2=middle, and 3=apical)

Table 1: A summary of the timeline, procedural steps, and radiographic findings.

Timeline	First visit	Second visit	Third visit	Fourth visit	Fifth visit
Procedures	Disinfection	Bleeding induction	6-month follow-up	10-month follow-up	22-month follow-up
Radiographic findings					
- Root length (mm)	-	10.80	-	-	11.56
- Root wall thickness (mm) [percentage change]					
Coronal	-	2.73	-	-	3.07 [12.66]
Middle	-	1.98	-	-	2.70 [36.73]
Apical	-	1.59	-	-	2.77 [74.06]
- Apical size (mm)	-	1.60	-	-	Closed apex
- Periapical lesion characteristics	Radiolucent area	Radiolucent area	Widening PDL space	Widening PDL space	Normal
- Periapical lesion size (mm)	6.4x3.3	4.2x2.3	-	-	-

PDL = Periodontal ligament

tial step in treatment success. In this case, 2.5% NaOCl was used as an irrigant, due to its well-established antimicrobial efficacy and tissue-dissolving properties.⁽²⁴⁾ An additional final rinse with 17% EDTA was performed prior to blood clot induction to facilitate the release of growth factors from dentin, which are essential for stem cell recruitment and tissue regeneration.⁽²⁵⁾ Ca(OH)₂ was selected as the intracanal material for its antibacterial effect and ability to support stem cell survival and proliferation.⁽²⁶⁻²⁸⁾ Previous studies have demonstrated that Ca(OH)₂ can induce the release of bioactive molecules from the dentin matrix, including transforming growth factor-β1 (TGF-β1), which may further contribute to regenerative success.^(25,29) This paste also offers practical advantages over antibiotic-based medications, such as reduced risk of antibiotic resistance and tooth discoloration.^(15,30) In this case, resolution of clinical symptoms was observed shortly after treatment, with radiographic evidence of periapical lesion reduction evident within 2 months. Complete healing of periapical tissues was confirmed by 22 months, consistent with previous reports.⁽¹²⁾ Therefore, the primary success criterion was satisfied.

Dental anesthetic solutions, with or without a vasoconstrictor, have been used for mixing with Ca(OH)₂ due to their availability, sterility, and ease of handling.⁽³¹⁾ Previous studies have demonstrated that anesthetic solutions combined with Ca(OH)₂ maintain pH values comparable to normal saline⁽³²⁾ and exhibit reduced surface tension, thereby enhancing their diffusion capacity.⁽³³⁾ Based on these properties, lidocaine with epinephrine was selected as the vehicle for mixing with Ca(OH)₂ in this case report.

As previously mentioned, Ca(OH)₂ medication has been consistently associated with apical closure, but not dentinal wall thickening.⁽⁸⁾ This may be linked to the ability of Ca(OH)₂ to facilitate calcium deposition at the apical region and its limited effect at the dentinal wall.⁽⁸⁾ Additionally, coronal placement of Ca(OH)₂ has been correlated with a greater increase in root wall thickness (53.8%) compared to placement beyond the coronal level (3.3%).⁽⁷⁾ However, the apical placement of Ca(OH)₂ in the present case produced a favorable secondary outcome; radiographic evaluation showed apical closure and root wall thickening at all evaluated levels. Additionally, the root length increased from 10.80 mm to 11.56 mm,

although it remained below the average adult root length of 14.5 mm.⁽³⁴⁾

The present findings correspond with those of previous studies.^(15,16) Intracanal application of Ca(OH)₂ in necrotic immature teeth led to periapical healing, continued root development, and a 45.4% increase in root wall thickness, compared to the 41.7% reported with antibiotic-based paste.⁽¹⁵⁾ Additionally, serial intracanal applications of Ca(OH)₂ in teeth with pulp necrosis and acute apical abscesses facilitated continued root development, especially root wall thickness and apical closure.⁽¹⁶⁾ These outcomes may reflect more effective disinfection and the stimulatory effects of Ca(OH)₂ on apical papilla stem cells^(28,35), which are essential for continued root maturation.^(35,36) Residual bacteria may hinder dentinal wall thickening, emphasizing the importance of effective microbial control during REPs.⁽³⁷⁾ In this instance, the apical application of Ca(OH)₂ may provide particular advantages in cases of complex or persistent infection by increasing disinfection in the apical region, thereby reducing the risk of reinfection and enhancing long-term outcomes.⁽¹⁹⁾ However, further investigation is necessary to elucidate the influence of different intracanal treatments and their placement on regenerative outcomes.

At the 10- and 22-month follow-up evaluations, the treated tooth remained non-responsive to sensibility testing, indicating that the tertiary goal of REPs had not been achieved. This outcome may relate to the use of a periapical bleeding scaffold, which has been associated with delayed recovery of pulp sensibility in some cases. Mittal *et al.*, reported that cold test responses may return as early as 3 months, whereas heat and EPT responses are rarely observed within 12 months.⁽³⁸⁾ Sensibility recovery has been demonstrated to be scaffold-dependent, with the highest rates observed in platelet-rich fibrin, followed by collagen, hydroxyapatite, and periapical bleeding; the latter typically showed responses around 12 months post-treatment. Additionally, radiographic evidence of radiopacity within the root canal space observed during follow-up may suggest the formation of calcific tissue, a finding reported in up to 78% of teeth treated with REPs.⁽³⁹⁾ Intracanal calcification may result from various contributing factors, including the type of scaffold and intracanal medications, especially Ca(OH)₂.^(39,40) Nonetheless, no further intervention is typically indicated unless the tooth becomes symptomatic.⁽⁶⁾

A bacteria-tight coronal seal is essential for the long-term success of REPs.⁽⁶⁾ Failure to maintain this seal may allow microbial ingress, leading to reinfection that can compromise stem cell proliferation and differentiation, ultimately impeding periapical healing and continued root development.⁽⁶⁾ At 10- and 22-month follow-ups, a secondary carious lesion was found, probably due to an inadequate coronal seal. The restoration was changed, oral hygiene instructions were repeated, and the patient was scheduled for follow-up. These indicate the necessity of a well-adapted coronal seal and effective clinical follow-up for long-term REPs success.

Although the current case report presents favorable clinical and radiological results, it is important to acknowledge some limitations. The lack of a histological evaluation limited the assessment of the actual internal tissue organization. Additionally, as the case represents a unique instance, the generalizability of the results is limited.

Conclusions

The favorable outcomes observed suggest that apical placement of Ca(OH)₂ during REPs may be a promising approach for managing immature teeth with pulp necrosis and chronic apical abscess, supporting both disinfection and root maturation.

Acknowledgments

We acknowledge Dr. Adjabhak Wongviriya for suggesting ImageJ measurement.

Funding

This case report did not receive any specific grant or funding from funding agencies in the public, commercial, or not-for-profit sectors.

Conflict of Interest

The authors declare that there are no conflict of interest regarding the publication of this case report.

References

1. Mohammadi Z. Strategies to manage permanent non-vital teeth with open apices: a clinical update. *Int Dent J*. 2011;61(1):25-30.
2. Levitan ME, Himel VT. Dens evaginatus: literature review, pathophysiology, and comprehensive treatment regimen. *J Endod*. 2006;32(1):1-9.
3. Kocsis G, Marcsik A, Kókai E, Kocsis K. Supernumerary occlusal cusps on permanent human teeth. *Acta Biol Szeged*. 2002;46(1-2):71-82.
4. Lerdrungroj K, Banomyong D, Songtrakul K, Porkaew P, Nakornchai S. Current management of dens evaginatus teeth based on pulpal diagnosis. *J Endod*. 2023;49(10):1230-7.
5. Trope M. Treatment of the immature tooth with a non-vital pulp and apical periodontitis. *Dent Clin North Am*. 2010;54(2):313-24.
6. Wei X, Yang M, Yue L, Huang D, Zhou X, Wang X, *et al*. Expert consensus on regenerative endodontic procedures. *Int J Oral Sci*. 2022;14(1):55.
7. Bose R, Nummikoski P, Hargreaves K. A retrospective evaluation of radiographic outcomes in immature teeth with necrotic root canal systems treated with regenerative endodontic procedures. *J Endod*. 2009;35(10):1343-9.
8. Báez V, Corcos L, Morgillo F, Imperatrice L, Gualtieri AF. Meta-analysis of regenerative endodontics outcomes with antibiotics pastes and calcium hydroxide. the apex of the iceberg. *J Oral Biol Craniofac Res*. 2022;12(1):90-8.
9. Wigler R, Kaufman AY, Lin S, Steinbock N, Hazan-Molina H, Torneck CD. Revascularization: a treatment for permanent teeth with necrotic pulp and incomplete root development. *J Endod*. 2013;39(3):319-26.
10. Ajram J, Khalil I, Gergi R, Zogheib C. Management of an immature necrotic permanent molar with apical periodontitis treated by regenerative endodontic protocol using calcium hydroxide and MM-MTA: a case report with two years follow up. *Dent J (Basel)*. 2019;7(1):1.
11. Park M, Ahn BD. Immature permanent teeth with apical periodontitis and abscess treated by regenerative endodontic treatment using calcium hydroxide and MTA: a report of two cases. *Pediatr Dent*. 2014;36(3):E107-10.
12. Chueh LH, Ho YC, Kuo TC, Lai WH, Chen YH, Chiang CP. Regenerative endodontic treatment for necrotic immature permanent teeth. *J Endod*. 2009;35(2):160-4.
13. Cehreli ZC, Isbitiren B, Sara S, Erbas G. Regenerative endodontic treatment (revascularization) of immature necrotic molars medicated with calcium hydroxide: a case series. *J Endod*. 2011;37(9):1327-30.
14. Pekpinarli B, Kaval ME, Cogulu D, Ilhan B, Sorsa T, Tervahartiala T, *et al*. The effect of calcium hydroxide and double antibiotic paste on radiographic outcomes and periapical MMP-8 levels in regenerative endodontic procedures: a randomized clinical trial. *J Appl Oral Sci*. 2024;32:e20240122.
15. Nagata JY, Gomes BP, Rocha Lima TF, Murakami LS, de Faria DE, Campos GR, *et al*. Traumatized immature teeth treated with 2 protocols of pulp revascularization. *J Endod*. 2014;40(5):606-12.
16. DeMayo FJ, Seagroves JT, Komabayashi T. Successful regenerative endodontic therapy of a dens evaginatus mandibular second premolar with an acute apical abscess and extensive periapical bone loss: a case report. *Eur J Dent*.

- 2025;19(1):255-64.
17. Cvek M. Prognosis of luxated non-vital maxillary incisors treated with calcium hydroxide and filled with gutta-percha. a retrospective clinical study. *Endod Dent Traumatol.* 1992;8(2):45-55.
 18. American Association of Endodontists. Clinical considerations for a regenerative procedure [Internet]. Chicago: American Association of Endodontists; 2021 May 18 [updated 2021 May 18; cited 2025 Feb 3]. Available from: <https://www.aae.org/specialty/wp-content/uploads/sites/2/2021/08/Clinical-Considerations-Approved-By-REC062921.pdf>.
 19. Silujjai J, Linsuwanont P. Treatment outcomes of apexification or revascularization in nonvital immature permanent teeth: a retrospective study. *J Endod.* 2017;43(2):238-45.
 20. Estefan BS, El Batouty KM, Nagy MM, Diogenes A. Influence of age and apical diameter on the success of endodontic regeneration procedures. *J Endod.* 2016;42(11):1620-5.
 21. Chueh LH, Huang GT. Immature teeth with periradicular periodontitis or abscess undergoing apexogenesis: a paradigm shift. *J Endod.* 2006;32(12):1205-13.
 22. Kim YJ, Chandler NP. Determination of working length for teeth with wide or immature apices: a review. *Int Endod J.* 2013;46(6):483-91.
 23. Mittal P, Jadhav GR, Logani A. Accuracy of different methods to determine working length in teeth with open apex-an *ex-vivo* comparative study. *J Dent Specialities.* 2016;4(1):39-45.
 24. Haapasalo M, Shen Y, Wang Z, Gao Y. Irrigation in endodontics. *Br Dent J.* 2014;216(6):299-303.
 25. Galler KM, Buchalla W, Hiller KA, Federlin M, Eidt A, Schiefersteiner M, *et al.* Influence of root canal disinfectants on growth factor release from dentin. *J Endod.* 2015;41(3):363-8.
 26. Nguyen V. The purpose of calcium hydroxide in root canal treatment. *IJRASET.* 2023;11(3):433-4.
 27. Safavi KE, Nichols FC. Effect of calcium hydroxide on bacterial lipopolysaccharide. *J Endod.* 1993;19(2):76-8.
 28. Ruparel NB, Teixeira FB, Ferraz CC, Diogenes A. Direct effect of intracanal medicaments on survival of stem cells of the apical papilla. *J Endod.* 2012;38(10):1372-5.
 29. Graham L, Cooper PR, Cassidy N, Nor JE, Sloan AJ, Smith AJ. The effect of calcium hydroxide on solubilisation of bio-active dentine matrix components. *Biomaterials.* 2006;27(14):2865-73.
 30. Galler KM, Krastl G, Simon S, Van Gorp G, Meschi N, Vahedi B, *et al.* European Society of Endodontology position statement: revitalization procedures. *Int Endod J.* 2016;49(8):717-23.
 31. Fava LR, Saunders WP. Calcium hydroxide pastes: classification and clinical indications. *Int Endod J.* 1999;32(4):257-82.
 32. Stamos DG, Haasch GC, Gerstein H. The pH of local anesthetic/calcium hydroxide solutions. *J Endod.* 1985;11(6):264-5.
 33. Ozcelik B, Taşman F, Oğan C. A comparison of the surface tension of calcium hydroxide mixed with different vehicles. *J Endod.* 2000;26(9):500-2.
 34. Nelson SJ. *Wheeler's Dental Anatomy, Physiology, & Occlusion.* 10th ed. St. Louis: Elsevier; 2015.
 35. Althumairy RI, Teixeira FB, Diogenes A. Effect of dentin conditioning with intracanal medicaments on survival of stem cells of apical papilla. *J Endod.* 2014;40(4):521-5.
 36. Van Le H, Nguyen TA, Vu TS. Regenerative endodontic procedures of immature permanent premolars with periapical lesions: a report of two cases using two different materials, 18-month follow-up. *Case Rep Dent.* 2023;5577474.
 37. de-Jesus-Soares A, Prado MC, Nardello LCL, Pereira AC, Cerqueira-Neto ACCL, Nagata JY, *et al.* Clinical and molecular microbiological evaluation of regenerative endodontic procedures in immature permanent teeth. *J Endod.* 2020;46(10):1448-54.
 38. Mittal N, Baranwal HC, Kumar P, Gupta S. Assessment of pulp sensibility in the mature necrotic teeth using regenerative endodontic therapy with various scaffolds - randomised clinical trial. *Indian J Dent Res.* 2021;32(2):216-20.
 39. Jiang X, Dai Y, Liu H. Evaluation of the characteristics of root canal calcification after regenerative endodontic procedures: a retrospective cohort study over 3 years. *Int J Paediatr Dent.* 2023;33(3):305-13.
 40. Song M, Cao Y, Shin SJ, Shon WJ, Chugal N, Kim RH, *et al.* Revascularization-associated intracanal calcification: assessment of prevalence and contributing factors. *J Endod.* 2017;43(12):2025-33.