



Editor:
Anak Iamaroon,
Chiang Mai University, Thailand.

Received: May 10, 2022
Revised: July 4, 2022
Accepted: September 13, 2022

Corresponding Author:
Associate Professor
Chairat Charoemratrote,
Department of Preventive Dentistry,
Faculty of Dentistry, Prince of Songkla
University, Songkhla 90112, Thailand.
E-mail: metalbracket@hotmail.com

Alveolar Bone Thickness and Height Changes after Maxillary Incisor Retraction and the Influencing Factors

Sinnapa Vanduangden¹, Chairat Charoemratrote², Steven J. Lindauer³, Shin-Jae Lee⁴

¹Orthodontic Resident, Orthodontic Section, Department of Preventive Dentistry, Faculty of Dentistry, Prince of Songkla University, Thailand

²Department of Preventive Dentistry, Faculty of Dentistry, Prince of Songkla University, Thailand

³Department of Orthodontics, School of Dentistry, Virginia Commonwealth University, USA

⁴Department of Orthodontics and Dental Research Institute, Seoul National University School of Dentistry, Korea

Abstract

Objectives: To evaluate the changes in alveolar bone after maxillary incisor (U1) retraction and factors influencing alveolar bone change.

Methods: A retrospective study was conducted in 95 adult patients (age 22.1±4.4 years) who required U1 retraction. Changes in U1 position were measured at the incisal edge (IE), cemento-enamel junction (CEJ), and root apex (AX). Changes in labial and palatal alveolar bone thickness (LaBT, PaBT) and height (LaBH, PaBH) were evaluated. Paired t-tests and Wilcoxon signed-rank test were used to determine significant changes from pre- to post-treatment. Multiple linear mixed effect analysis was used to evaluate factors influencing alveolar bone thickness changes after U1 retraction.

Results: After U1 retraction, LaBT was maintained at all levels. PaBT thinned significantly at the crestal and mid-root levels. Significant bone height reduction occurred at LaBH and PaBH. Alveolar bone thickness changes on the palatal side were negatively proportional to alveolar bone thickness changes on the labial side. Alveolar bone thickness change was more conspicuous at the apical level compared to the crestal level. Alveolar bone thickness change was proportional to the amount of intrusion at the AX and was negatively proportional to bone height reduction.

Conclusions: LaBT was maintained, whereas PaBT, LaBH, and PaBH had significant loss after U1 retraction. Labial and palatal sides, levels of bone thickness measurements, amount of AX intrusion, and bone height reduction are significant factors that may influence alveolar bone thickness and height changes after U1 retraction.

Keywords: alveolar bone, lateral cephalometric radiograph, maxillary incisor retraction, root apex intrusion

Introduction

Maxillary incisor (U1) protrusion motivates patients to undergo orthodontic treatment.⁽¹⁾ Extraction of maxillary premolars followed by U1 retraction is a widely used approach to improve occlusion and esthetics.^(2,3) Many studies have focused on changes in alveolar bone thickness after U1 retraction. Most found that alveolar bone labial to the U1 increased in thickness⁽⁴⁻⁷⁾ or maintained its original thickness,^(8,9) while palatal alveolar bone thickness decreased^(5,7,8,10) or maintained its original thickness.⁽⁴⁾ Most previous studies were conducted in growing subjects in whom dentoalveolar growth may affect the alveolar bone changes.^(5,6,8-10) A study by Yodthong *et al.*⁽⁴⁾ in U1 retraction was conducted in adult subjects but the sample size was small. In addition, U1 retraction caused loss of alveolar bone height. The greatest crestal bone loss was observed in palatal bone, followed by labial bone.^(7,11,12)

The amount of tooth movement is likely an important factor affecting changes in alveolar bone during orthodontic treatment. Most studies used the incisal edge (IE) as a reference point to measure the amount of tooth movement.^(4,6) Although IE is commonly used to evaluate tooth movement clinically, the part of the tooth that contacts the alveolar bone is actually the root. Therefore, the amount of tooth movement at the cemento-enamel junction (CEJ) and root apex (AX) could be better markers for studying changes in the alveolar bone.

Cone-beam computed tomography (CBCT) provides anatomically accurate images in 3D. Therefore, evaluation of alveolar bone changes after U1 retraction is often accomplished with CBCT.^(4,5,8-10) Usually, a lateral cephalogram is used for orthodontic evaluation, diagnosis, and treatment planning. CBCT with its inevitable additional radiation and cost is indicated for more complex cases to establish a diagnosis and treatment plan.^(13,14) Five studies evaluated labial alveolar bone thickness (LaBT) changes after U1 retraction by CBCT. Two studies reported a significant increase in LaBT at the crestal level,^(4,5) and one study reported a significant increase in LaBT at the apical level.⁽¹⁵⁾ However, two studies reported no significant changes in LaBT.^(8,9) Only one study evaluated LaBT changes by lateral cephalogram. The study reported a significant increase in LaBT at the apical level.⁽⁶⁾ Five studies evaluated palatal alveolar bone thickness (PaBT) changes by CBCT after U1 retraction. Two studies

reported a significant decrease in PaBT at the crestal and mid-root levels.^(5,8) One study reported a significant increase in PaBT at the crestal level and a decrease at the apical level.⁽⁹⁾ However, two studies reported no significant changes in PaBT,^(4,15) and no study evaluated PaBT changes by lateral cephalogram. Three studies evaluated labial and palatal alveolar bone height (LaBH and PaBH) changes by CBCT after U1 retraction. All previous studies found significant loss of PaBH^(7,11,16) but only one study found significant loss of LaBH.⁽⁷⁾ Treatment durations, skeletal types, amount of tooth movement, and age may lead to different study results.

This study aimed to evaluate changes in alveolar bone after U1 retraction in adult patients using lateral cephalometric radiographs and determine the associations between those changes and variables related to the four incisor reference points: IE, labial CEJ (LaCEJ), palatal CEJ (PaCEJ) and AX.

Materials and Methods

Sample

This retrospective study was performed after approval from the Ethics Committee, Faculty of Dentistry, Prince of Songkla University. The population included patients who started and completed treatment with a fixed orthodontic appliance in the Orthodontic Clinic, Faculty of Dentistry, Prince of Songkla University between 2012 and 2019. A flow chart of sample recruitment is shown in Figure 1. All patients were treated with preadjusted bidimensional edgewise fixed appliances (Roth's prescription; 0.018×0.025-in slots on incisors and 0.022×0.028-in slots on canines and posterior teeth). The inclusion criteria were (1) adult patients (17-35 years old) who received conventional orthodontic treatment and extraction of two maxillary first premolars with U1 retraction more than 2 mm, (2) skeletal Class II with U1 protrusion ($4^\circ < \text{ANB} < 9^\circ$, U1-NA > 5 mm), (3) no craniofacial deformity, (4) no medical history related to bone metabolism, and (5) good quality lateral cephalograms and the same x-ray machine for both T0 and T1 radiographs. The exclusion criteria were (1) patients with previous orthodontic treatment or orthognathic surgery, (2) periodontal and gingival diseases, (3) restorations or root canal treatment on the U1, (4) history of U1 trauma, and (5) supernumerary teeth, impacted teeth or missing teeth in the anterior region of the maxilla.

Sample size calculation

Since no similar studies existed, a pilot study was conducted in 20 randomly selected subjects. The sample size calculation was estimated at a power of 80% and a 0.05 level of significance using G*Power software version 3.1.9.4 (Franz Faul; Christian-Albrechts-Universitat, Kiel, Germany). The pilot study estimated an effect size of 0.266. Eventually, a sample size of 73 subjects was required.

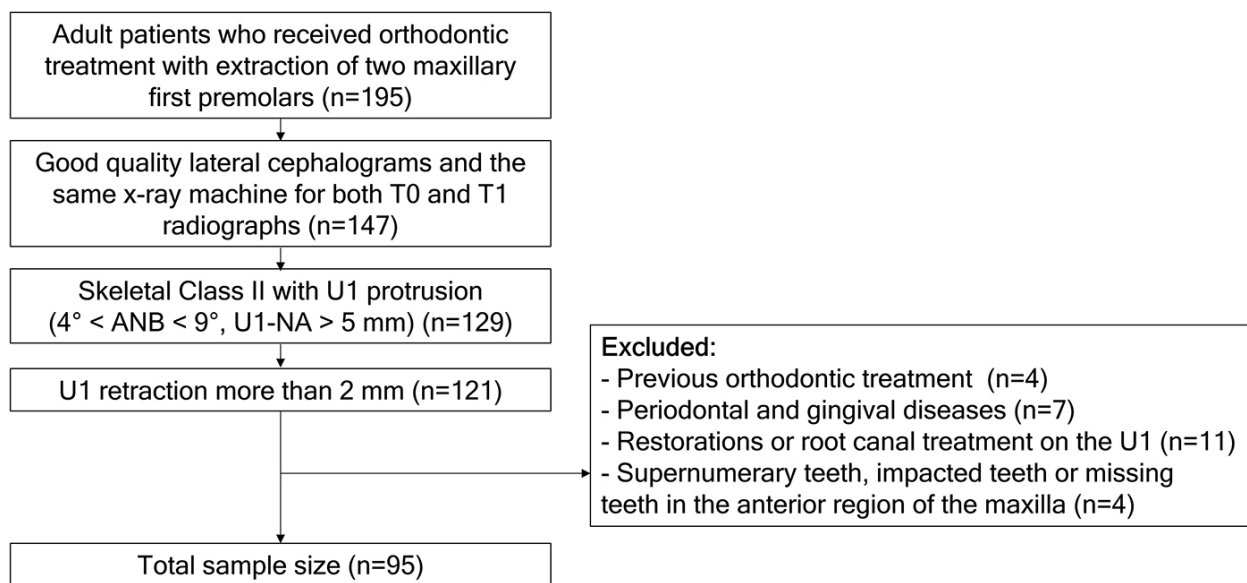


Figure 1: Flow chart of sample recruitment.

Cephalometric analysis

Lateral cephalograms were taken with three x-ray machines: Orthophos (Siemens, Fernwald, Germany), GXDP-300 (Gendex, Tuusula, Finland), and Orthopantomograph® OP300 (Instrumentarium, Tuusula, Finland) with magnifications of 9.34%, 10.41%, and 10.45% respectively. All lateral cephalograms were obtained in the natural head position with teeth in maximum intercuspation and passive lips.

T0 and T1 lateral cephalograms were manually traced with 0.003-inch acetate paper with a 0.3 mm 2H lead mechanical pencil. Each tracing was scanned as a JPEG image. An appropriate correction for enlargement was performed during the process of analysis by ImageJ software (version 1.53a, NIH, Bethesda, MD, USA). All measurements were performed twice to reduce measurement error, and the mean value was calculated and used for evaluation. The cephalometric landmarks and lines

are shown in Table 1, and the cephalometric variables are shown in Table 2.

1. Assessment of U1 inclination and position

Angular and linear measurements of the U1 teeth were evaluated on lateral cephalometric tracings to determine both inclination and position (Figure 2). The points and planes were analyzed using a modified Pancherz analysis.⁽¹⁷⁾ The horizontal reference line of the T0 and

T1 radiographs was the functional occlusal plane (OP) of the T0 radiograph. The vertical reference line was the occlusal plane vertical (OPV), which was a line perpendicular to OP passing through S of the T0 radiograph. OP and OPV were transferred from the T0 to T1 radiographs by superimposing the T1 tracing over the T0 tracing. The inclination of U1 was measured as the angle between the U1 long axis and the palatal plane (U1-PP). The horizontal and vertical U1 positions were measured as distances between IE, LaCEJ, PaCEJ and AX to the OPV and OP lines.

2. Assessment of alveolar bone

Changes in alveolar bone were evaluated by both thickness and height. The LaBT and PaBT were measured at the crestal (S1), mid-root (S2), and apical (S3) levels apical to the CEJ line every 3 mm (Figure 3).⁽⁸⁾ Labial and palatal alveolar bone height (LaBH and PaBH) were

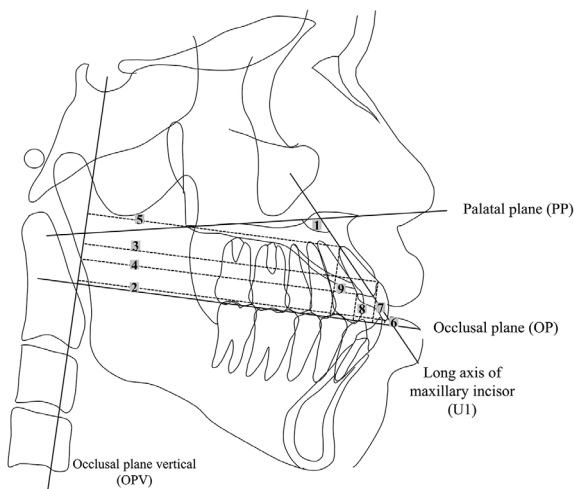


Figure 2: Angular and linear measurements at pre- and post-treatment: (1) U1-PP; (2) IE-OPV; (3) LaCEJ-OPV; (4) PaCEJ-OPV; (5) AX-OPV; (6) IE-OP; (7) LaCEJ-OP; (8) PaCEJ-OP; and (9) AX-OP.

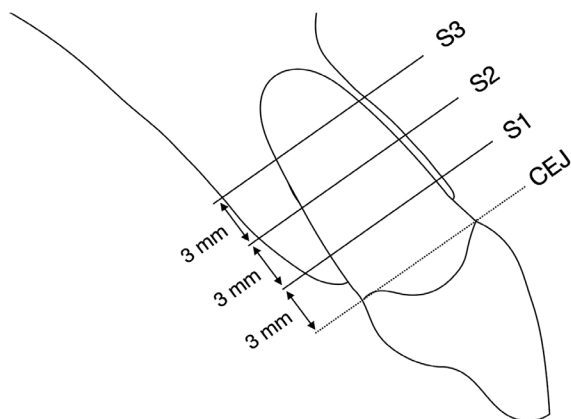


Figure 3: Measurements of LaBT and PaBT of the U1 were performed at three levels (S1, S2, and S3).

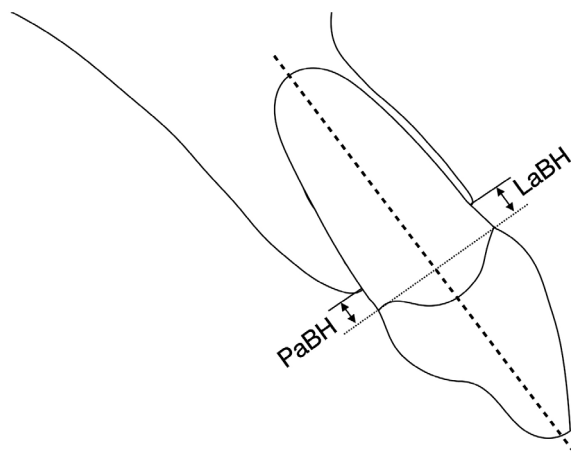


Figure 4: LaBH and PaBH were measured as the distances between the CEJ and the alveolar bone crest.

measured from the CEJ to the alveolar crest parallel to the long axis (Figure 4).⁽¹⁸⁾

Statistical analysis

Ten randomly selected lateral cephalograms were traced and remeasured after an interval of four weeks to assess the intra- and inter-rater reliability using Dahlberg's formula and intraclass correlation coefficient (ICC). This study was performed by two examiners, both Thai Board of Orthodontics certified clinicians and full-time educators in an academic institution. Calibration between the two examiners was performed before formal analysis.

Shapiro-Wilk tests showed a normal distribution of the inclination and position of U1 data but non-normal distribution of the alveolar bone data. Consequently, paired t-tests were used to evaluate changes in the U1 position and inclination between T0 and T1. Wilcoxon signed-rank test was used to evaluate alveolar bone changes between T0 and T1. To evaluate significant factors that influenced alveolar bone thickness change after U1 retraction, a mixed effect model was applied to control the random effects from individual subjects. Statistical analyses were carried out using Language R (R Development Core Team, Vienna, Austria). The significance level of all tests was established at 0.05.

Results

Ninety-five patients (85 females and 10 males) were available for the analysis. The means of ANB and U1-NA at T0 were $5.18 \pm 1.01^\circ$ (range 4.02-8.88) and 7.59 ± 1.53 mm (range 5.06-10.92), respectively. The means of age and treatment time were 22.10 ± 4.41 years (range 17.01-34.97) and 3.61 ± 0.93 years (range 1.70-6.25), respectively.

1. Assessment of U1 inclination and position

After treatment, U1 had tipped significantly palatally by a mean of 13.85° ($p < 0.001$) (Table 1). All tooth reference points for horizontal movement (IE, LaCEJ, PaCEJ, and AX) were retracted significantly palatally ($p < 0.001$). IE demonstrated the greatest palatal movement (5.83 mm) followed by PaCEJ (4.01 mm), LaCEJ (3.30 mm), and AX (1.15 mm). Significant extrusion was observed in the vertical plane at IE (1.72 mm) and LaCEJ (1.16 mm), whereas PaCEJ was maintained without a significant difference. AX intruded significantly (1.19 mm).

Table 1: Definitions of cephalometric landmarks and planes.

Landmarks and planes	Definition
Landmarks	
S (Sella)	The center of the hypophyseal fossa
N (Nasion)	The most anterior point of the frontonasal suture which joins the nasal part of the frontal bone and nasal bone
A (Point A)	The deepest point of the anterior border of the maxillary alveolar ridge concavity
B (Point B)	The deepest point of the anterior border of the mandible alveolar ridge concavity
ANS (Anterior nasal spine)	The tip of the anterior nasal spine
PNS (Posterior nasal spine)	The tip of the posterior nasal spine
IE (Incisal edge)	The incisal tip of the most anterior maxillary central incisor
LaCEJ (Labial CEJ)	The labial cemento-enamel junction of the most anterior maxillary central incisor
PaCEJ (Palatal CEJ)	The palatal cemento-enamel junction of the most anterior maxillary central incisor
AX (Apex)	The root apex of the most anterior maxillary central incisor
Planes	
U1	The long axis of the most anterior maxillary central incisor
NA	The line between the nasion and point A
NB	The line between the nasion and point B
PP (Palatal plane)	The line between the anterior nasal spine and posterior nasal spine
OP (Occlusal plane)	The line bisecting the molars and premolar overlaps of the pre-treatment radiograph
OPV (Occlusal plane vertical)	The line perpendicular to the occlusal plane passing through S of the pre-treatment radiograph

Table 2: Definitions of cephalometric variables.

Variables	Definitions
ANB (°)	The angle formed by A, N, and B indicating the skeletal relationship between the maxilla and mandible
U1-PP (°)	The angle formed by the long axis of the most anterior maxillary central incisor and the palatal plane
U1-NA (mm)	The distance from the incisal tip of the most anterior maxillary central incisor to the NA line
IE-OPV (mm)	The distance from the incisal tip of the most anterior maxillary central incisor to the occlusal plane vertical
LaCEJ-OPV (mm)	The distance from the labial CEJ of the most anterior maxillary central incisor to the occlusal plane vertical
PaCEJ-OPV (mm)	The distance from the palatal CEJ of the most anterior maxillary central incisor to the occlusal plane vertical
AX-OPV (mm)	The distance from the root apex of the most anterior maxillary central incisor to the occlusal plane vertical
IE-OP (mm)	The distance from the incisal tip of the most anterior maxillary central incisor to the occlusal plane
LaCEJ-OP (mm)	The distance from the labial CEJ of the most anterior maxillary central incisor to the occlusal plane
PaCEJ-OP (mm)	The distance from the palatal CEJ of the most anterior maxillary central incisor to the occlusal plane
AX-OP (mm)	The distance from the root apex of the most anterior maxillary central incisor to the occlusal plane
LaBT at S1 (mm)	The labial alveolar bone thickness at the crestal level: the distance from the labial cortical plate to the labial root surface at 3 mm apical to the CEJ line
LaBT at S2 (mm)	The labial alveolar bone thickness at the mid-root level: the distance from the labial cortical plate to the labial root surface at 6 mm apical to the CEJ line
LaBT at S3 (mm)	The labial alveolar bone thickness at the apical level: the distance from the labial cortical plate to the labial root surface at 9 mm apical to the CEJ line
PaBT at S1 (mm)	The palatal alveolar bone thickness at the crestal level: the distance from the palatal cortical plate to the palatal root surface at 3 mm apical to the CEJ line
PaBT at S2 (mm)	The palatal alveolar bone thickness at the mid-root level: the distance from the palatal cortical plate to the palatal root surface at 6 mm apical to the CEJ line
PaBT at S3 (mm)	The palatal alveolar bone thickness at the apical level: the distance from the palatal cortical plate to the palatal root surface at 9 mm apical to the CEJ line
LaBH (mm)	The labial alveolar bone height: the distance formed from the labial CEJ of the most anterior maxillary central incisor to the labial alveolar crest parallel to the long axis
PaBH (mm)	The palatal alveolar bone height: the distance formed from the palatal CEJ of the most anterior maxillary central incisor to the palatal alveolar crest parallel to the long axis

Table 3: Comparisons of mean inclination and position of U1 at T0 and T1 with paired *t*-test.

	T0	T1	T0-T1	<i>p</i> -value
Inclination (°)	122.79±6.06	108.94±6.84	13.85±5.50	<0.001**
Horizontal plane (mm)				
IE	85.53±4.24	79.70±4.23	5.83±1.42	<0.001**
LaCEJ	80.64±4.58	77.34±4.41	3.30±1.31	<0.001**
PaCEJ	76.65±4.01	72.64±3.89	4.01±1.35	<0.001**
AX	70.09±4.01	68.94±3.76	1.15±1.74	<0.001**
Vertical plane (mm)				
IE	0.27±1.31	-1.45±1.18	1.72±1.25	<0.001**
LaCEJ	10.62±2.46	9.46±2.30	1.16±1.12	<0.001**
PaCEJ	6.36±1.65	6.37±1.77	-0.01±0.96	0.902
AX	17.71±1.29	18.90±1.46	-1.19±0.99	<0.001**

Values are presented as mean ± standard deviation. **: *p*<0.001.

Inclination: retroclination (+), proclination (-). Horizontal plane: palatal movement (+), labial movement (-). Vertical plane: extrusion (+), intrusion (-).

Table 4: Comparisons of mean alveolar bone thicknesses and heights at T0 and T1 with Wilcoxon signed-rank test.

	T0	T1	T1-T0	<i>p</i> -value
LaBT				
S1	0.96±0.34	0.99±0.41	0.03±0.49	0.280
S2	1.25±0.45	1.39±0.60	0.14±0.71	0.090
S3	1.85±0.72	2.06±0.97	0.21±1.10	0.062
PaBT				
S1	1.41±0.55	0.71±0.67	-0.70±0.71	<0.001**
S2	2.70±0.77	2.05±1.14	-0.65±1.11	<0.001**
S3	3.73±0.97	3.67±1.48	-0.06±1.45	0.646
LaBH	-1.05±0.36	-1.16±0.42	-0.11±0.45	0.044*
PaBH	-1.21±0.41	-2.49±1.59	-1.28±1.59	<0.001**

Values are presented as the mean ± standard deviation. *: *p*<0.05, **: *p*<0.001. Alveolar bone thickness and height: bone gain (+), bone loss (-).

Table 5: Statistically significant factors (multiple linear mixed effect analysis) affecting alveolar bone thickness changes after U1 retraction according to changes in the tooth position (IE, CEJ, and AX), labial and palatal sides, levels of bone thickness measurements, and bone height reduction.

Variables	β	SE (β)	<i>p</i> -value
Labial vs palatal side			
Labial side	Reference		
Palatal side	-0.20	0.08	0.016*
Levels of bone thickness measurements			
S1	Reference		
S2	0.08	0.09	0.375
S3	0.41	0.09	<0.001**
Amount of intrusion at AX (mm)	0.13	0.04	<0.001**
Bone height reduction (mm)	-0.33	0.03	<0.001**

*: *p*<0.05, **: *p*<0.001.

Table 6: Intra- and inter-rater reliability using Dahlberg's formula and intraclass correlation coefficients for linear and angular cephalometric measurements.

Variables	Intra-rater reliability			Inter-rater reliability		
	ICC	95% CI	D	ICC	CI 95%	D
ANB (°)	0.961	0.852-0.990	0.254	0.993	0.971-0.998	0.253
U1-PP (°)	0.995	0.980-0.999	0.493	0.996	0.985-0.999	0.492
U1-NA (mm)	0.966	0.869-0.991	0.357	0.976	0.906-0.994	0.307
IE-OPV (mm)	0.994	0.974-0.998	0.383	0.997	0.990-0.999	0.275
LaCEJ-OPV (mm)	0.990	0.961-0.998	0.365	0.995	0.979-0.999	0.308
PaCEJ-OPV (mm)	0.986	0.946-0.997	0.427	0.998	0.992-0.999	0.266
AX-OPV (mm)	0.981	0.926-0.995	0.433	0.994	0.976-0.999	0.348
IE-OP (mm)	0.994	0.976-0.999	0.135	0.994	0.976-0.999	0.076
LaCEJ-OP (mm)	0.960	0.847-0.990	0.314	0.977	0.911-0.994	0.132
PaCEJ-OP (mm)	0.995	0.979-0.999	0.109	0.949	0.810-0.987	0.178
AX-OP (mm)	0.960	0.849-0.990	0.235	0.967	0.873-0.992	0.237
LaBT at S1 (mm)	0.960	0.849-0.990	0.054	0.964	0.862-0.991	0.036
LaBT at S2 (mm)	0.982	0.929-0.996	0.046	0.975	0.901-0.994	0.041
LaBT at S3 (mm)	0.991	0.964-0.998	0.071	0.974	0.898-0.993	0.072
PaBT at S1 (mm)	0.972	0.893-0.993	0.082	0.932	0.753-0.983	0.139
PaBT at S2 (mm)	0.970	0.883-0.992	0.102	0.953	0.825-0.988	0.097
PaBT at S3 (mm)	0.955	0.829-0.989	0.074	0.988	0.951-0.997	0.115
LaBH (mm)	0.903	0.659-0.975	0.144	0.990	0.959-0.997	0.080
PaBH (mm)	0.979	0.919-0.995	0.113	0.918	0.707-0.979	0.131

ICC: Intraclass correlation coefficient, CI: Confidence interval, D: Dahlberg's formula value

2. Assessment of alveolar bone

The mean changes in alveolar bone are shown in Table 2. LaBT showed no significant differences in thickness at any level of measurement from pre- to post-treatment, while PaBT at S1 and S2 showed significant bone thickness decreases of 0.70 mm and 0.65 mm, respectively, and no significant difference at S3 ($p=0.646$). Losses of bone at LaBH and PaBH were significant with more loss observed on the palatal side (1.28 mm) than the labial side (0.11 mm).

3. Factors influencing alveolar bone thickness changes (Multiple linear mixed effect analysis)

Alveolar bone thickness changes on the palatal side were negatively proportional to alveolar bone thickness changes on the labial side ($p=0.016$). A one-millimeter increase in LaBT resulted in a 0.2 mm decrease in the PaBT on average. Alveolar bone thickness change was more conspicuous at S3 compared to S1 ($p<0.001$). Alveolar bone thickness change was proportional to the amount

of intrusion at AX ($p<0.001$) and was negatively proportional to the bone height reduction ($p<0.001$) (Table 3).

4. Measurement error

The intra- and inter-rater reliability results using Dahlberg's formula values and ICC calculations for linear and angular cephalometric measurements are shown in Table 6. The reliability analysis showed excellent intra- and inter-rater reliability.

Discussion

As expected, following U1 retraction to reduce incisor protrusion, the incisors were uprighted by an average of 13.85°, which brought them closer to the esthetic cephalometric values in the Thai population.⁽¹⁹⁾ During U1 retraction, the force was applied at the bracket, whereas the center of resistance of the four maxillary incisors was approximately 4.3 mm apically to the height of the palatal bone.⁽²⁰⁾ Therefore, tipping movement occurred because the force was not acting through the center of resistance.

Therefore, the reference point IE moved palatally more than the points on the root of the tooth. The least palatal movement occurred at AX, depending on the initial incisal inclination and the amount of labial crown torque applied during retraction. Large amounts of uprighting in some cases were probably associated with uncontrolled tipping that could have moved the root apex toward the labial bone. Various types of U1 movement during retraction were previously demonstrated using superimposition of pre-and post-treatment images.^(4,21) Therefore, if bone remodeling is proportional to the amount of tooth movement that occurs,^(22,23) using IE as a reference point for tooth position would overestimate bone response.

Similarly, IE extruded vertically by an average of 1.72 mm, whereas only the LaCEJ extruded less (1.16 mm) and PaCEJ showed almost no vertical change (0.01 mm). Interestingly, AX intruded by over 1 mm on average, which was consistent with uncontrolled tipping, and demonstrated that IE movement did not represent the type of movement occurring at the various root landmarks and, therefore, insufficient to explain changes observed in the alveolar bone.

LaBT showed no significant changes at the three levels after U1 retraction, which indicated neither bone gain nor bone loss occurred. This agreed with the results of previous studies.^(8,9) However, another study⁽⁴⁾ reported thickening of bone on the labial side that was attributed to a delay in bone resorption as the incisors were retracted rapidly.

PaBT decreased at S1 and S2, which was consistent with the pressure expected from tooth tipping since these two levels were coronal to the center of rotation during incisor uprighting. At T0, the thicknesses at S1 and S2 were 1.41 and 2.70 mm, which reduced by 0.70 mm and 0.65 mm, respectively, after 4.01 mm palatal movement of PaCEJ. Thinning of the PaBT indicated that resorption on the labial side of the palatal bone was more than the apposition on the palatal side of the palatal bone. At S3, no significant changes occurred in bone thickness after an average palatal AX movement of 1.15 mm. This was possibly due to AX movement that was too small for measurable changes in bone thickness. Palatal bone changes observed in the current study were consistent with some previous studies.^(5,8) However, others reported significant decreases in PaBT also at the level of the incisor apex,^(7,9,10) and some studies found a non-statistically

significant decrease in the PaBT at all three levels.⁽⁴⁾ Various types of tooth movement among the studies may explain the different findings.

In this study, U1 retraction caused statistically significant losses of LaBH and PaBH and PaBH had greater loss than LaBH, which agreed with previous studies.^(7,11,12) A small (0.11 mm) but significant loss of LaBH was observed even while extrusion of the LaCEJ (1.16 mm) took place. This was possibly due to excessive force levels that delayed bone formation.⁽²⁴⁾

From the multiple linear mixed effect model analysis, alveolar bone thickness changes on the palatal side were negatively proportional to the labial side changes. Therefore, one millimeter of labial bone increase would result in 0.2 mm palatal bone thinning on average. However, labial bone increased a little but not significantly (Table 2). A statistical analysis performed as separate variables (Table 2) could not detect this increase of labial bone. However, pooling the variables revealed significant increases in labial bone (Table 3).

Alveolar bone thickness change was more obvious at S3 compared to S1. This implied that LaBT at S3 would gain more than S1, whereas the PaBT at S3 would decrease less than S1 after U1 retraction. Gain of LaBT is a benefit for periodontal health, while loss of PaBT is a concern that would happen more at S1. Therefore, the clinician must place importance on the initial PaBT, especially on the thin PaBT at the crestal level.

Alveolar bone thickness change was proportional to the amount of intrusion at AX. Actually, four reference points (IE, LaCEJ, PaCEJ and AX) were studied with their movement in both antero-posterior and vertical directions. However, from the multiple linear mixed effect model analysis only AX moved in the vertical direction as intrusion showed a significant association. The more intrusion at AX, the more bone gain. The β in Table 3 implies that 1 mm of AX intrusion relates to 0.13 mm of alveolar bone thickness overall. Since intrusion would move the tooth into a wider alveolar bone housing and subsequently provide more alveolar support and compensating palatal bone resorption,^(16,25) clinicians must be cognizant that excessive intrusion force can lead to apical root resorption.⁽²⁶⁾ Even though intrusion at IE failed to show an association with bone thickness changes, other studies^(4,6) indicated that intrusion at IE was related to alveolar bone gain at the apical level. This could be from

substantial variation in bone changes among individuals and the reference point methods, bone thickness measurements, and the statistical analysis methods.

Alveolar bone thickness changes were negatively proportional to the bone height reduction. The β in Table 3 explains that alveolar bone thickness decreased by 0.33 mm when bone height reduced by 1 mm. This reveals an association between the changes of bone thickness and bone height. Tooth movements that cause bone height loss could simultaneously reduce bone thickness.

Anatomical structures are accurately depicted in 3D using CBCT. Consequently, CBCT is often used to evaluate alveolar bone changes after U1 retraction.^(4,5,8-10) However, since CBCT exposes patients to ionization radiation and additional cost, CBCT is usually used for more complex dental problems.^(13,14) Therefore, studies based on CBCT are usually conducted using small sample sizes, which usually reduces the power of the studies.⁽²⁷⁾ Moreover, cephalometric analysis is also regularly applied for alveolar bone evaluation before and after treatment in clinical practice. In this study, A large sample of lateral cephalometric radiographs were used to evaluate the changes in alveolar bone after U1 retraction and factors influencing alveolar bone change.

Most previous studies of alveolar bone thickness changes after U1 retraction were conducted in growing subjects.^(5,6,8-10) However, dentoalveolar growth may affect the alveolar bone changes and the amount of tooth movement.⁽²⁷⁾ An implant study found the dentition drifted forward and downward in growing subjects.⁽²⁸⁾ Therefore, the amount of retraction and extrusion were less than the actual tooth movement in growing subjects. A study by Yodthong *et al.*⁽⁴⁾ used CBCT to measure alveolar bone thickness changes in adult subjects; however, the study had a small sample size and the amount of tooth movement was measured at IE only.

IE is commonly used in studies as a landmark to measure orthodontic tooth movement. However, bone changes during incisor retraction were dependent on both the amount of linear tooth displacement and changes in axial inclination, as previously reported.⁽¹⁶⁾

The reference plane for measuring the magnitude of tooth movement was along the OP. Since this study aimed to evaluate changes in alveolar bone following U1 retraction, bone was evaluated relative to the tooth

long axis using methods previously established in other studies.⁽⁴⁻¹⁰⁾

The results of this study can be applied when visual treatment objectives are performed for treatment planning. The superimposition between initial and planned tracings would indicate how the maxillary incisor should be moved. Intrusion at AX would provide either more LaBT gain or less PaBT thinning after U1 retraction. Thin palatal alveolar bone must be considered for the appropriate retraction distance.

This study had some limitations. First, the mean age of patients was 22.1 ± 4.4 years, which did not properly represent the adult population. Second, since this study was limited by its retrospective design, the patients were not treated with the same biomechanics, radiographic protocol, x-ray machines, and orthodontist. In addition, since only the initial and final cephalograms were compared, long-term alveolar bone changes were not determined.

Conclusions

After maxillary incisor retraction,

- LaBT did not change significantly but LaBH decreased by an average of 0.1 mm while both PaBT and PaBH decreased.
- The labial and palatal sides, levels of bone thickness measurements, amount of AX intrusion, and bone height reduction affected alveolar bone thickness changes.
- Alveolar bone thickness changes were greater at S3 than S1.
- Intrusion at AX was related to alveolar bone gain at the apical level.
- Alveolar bone thickness decreased, whereas a reduction in alveolar bone height was observed.

Acknowledgments

We would like to thank the Graduate School and the Faculty of Dentistry, Prince of Songkla University for grant support.

Conflict of interest

The authors declare no conflict of interest.

References

1. Foster T, Walpole Day A. A survey of malocclusion and the need for orthodontic treatment in a Shropshire school population. *Br J Orthod.* 1974;1(3):73-8.

2. Hayashida H, Ioi H, Nakata S, Takahashi I, Counts AL. Effects of retraction of anterior teeth and initial soft tissue variables on lip changes in Japanese adults. *Eur J Orthod.* 2011;33(4):419-26.
3. Makino M, Choi YY, Nojima K, Nishii Y, Sueishi K. Characteristics of dentoskeletal morphology and treatment changes in 2-maxillary premolar extraction: a comparison with 4-premolar extraction. *J World Fed Orthod.* 2013;2(2):e71-e6.
4. Yodthong N, Charoemratrote C, Leethanakul C. Factors related to alveolar bone thickness during upper incisor retraction. *Angle Orthod.* 2012;83(3):394-401.
5. Picanço PRB, Valarelli FP, Cançado RH, Freitas KMSd, Picanço GV. Comparison of the changes of alveolar bone thickness in maxillary incisor area in extraction and non-extraction cases: computerized tomography evaluation. *Dental Press J Orthod.* 2013;18(5):91-8.
6. Hong SY, Shin JW, Hong C, Chan V, Baik UB, Kim YH, *et al.* Alveolar bone remodeling during maxillary incisor intrusion and retraction. *Prog Orthod.* 2019;20(1):1-8.
7. Ahn HW, Moon SC, Baek SH. Morphometric evaluation of changes in the alveolar bone and roots of the maxillary anterior teeth before and after en masse retraction using cone-beam computed tomography. *Angle Orthod.* 2012;83(2):212-21.
8. Sarikaya S, Haydar B, Çiğir S, Ariyürek M. Changes in alveolar bone thickness due to retraction of anterior teeth. *Am J Orthod Dentofacial Orthop.* 2002;122(1):15-26.
9. Krishna UN, Shetty A, Giriya M, Nayak R. Changes in alveolar bone thickness due to retraction of anterior teeth during orthodontic treatment: a cephalometric and computed tomography comparative study. *Indian J Dent Res.* 2013;24(6):736-41.
10. Singh A, Chandra S, Agarwal D, Bhattacharya P. A study to evaluate the alveolar bone thickness during anterior retraction using computed tomography. *Int J Contemp Med Res.* 2017;4(5):1021-6.
11. Zhang F, Lee SC, Lee JB, Lee KM. Geometric analysis of alveolar bone around the incisors after anterior retraction following premolar extraction. *Angle Orthod.* 2020;90(2):173-80.
12. Lund H, Gröndahl K, Gröndahl HG. Cone beam computed tomography evaluations of marginal alveolar bone before and after orthodontic treatment combined with premolar extractions. *Eur J Oral Sci.* 2012;120(3):201-11.
13. American Academy of Oral and Maxillofacial Radiology. Clinical recommendations regarding use of cone beam computed tomography in orthodontics. position statement by the American Academy of Oral and Maxillofacial Radiology. *Oral Surg Oral Med Oral Pathol Oral Radiol.* 2013;116(2):238-57.
14. Van Bunningen R, Dijkstra P, Dieters A, van der Meer W, Kuijpers-Jagtman AM, Ren Y. Precision of orthodontic cephalometric measurements on ultra low dose-low dose CBCT reconstructed cephalograms. *Clin Oral Investig.* 2022;26(2):1543-50.
15. Shah A. Changes in alveolar bone thickness during upper incisor retraction. *Guident.* 2017;10(12):46-53.
16. Mao H, Yang A, Pan Y, Li H, Lei L. Displacement in root apex and changes in incisor inclination affect alveolar bone remodeling in adult bimaxillary protrusion patients: a retrospective study. *Head Face Med.* 2020;16(1):1-12.
17. Pancherz H. A cephalometric analysis of skeletal and dental changes contributing to class II correction in activator treatment. *Am J Orthod.* 1984;85(2):125-34.
18. Chaimongkol P, Thongudomporn U, Lindauer SJ. Alveolar bone response to light-force tipping and bodily movement in maxillary incisor advancement: a prospective randomized clinical trial. *Angle Orthod.* 2017;88(1):58-66.
19. Sutthiprapaporn P, Manosudprasit A, Pisek A, Manosudprasit M, Pisek P, Phaoseeree N, *et al.* Establishing esthetic lateral cephalometric values for Thai adults after orthodontic treatment. *Khon Kaen Dent J.* 2020;23(2):31-41.
20. Yoshida N, Koga Y, Mimaki N, Kobayashi K. *In vivo* determination of the centres of resistance of maxillary anterior teeth subjected to retraction forces. *Eur J Orthod.* 2001;23(5):529-34.
21. Vardimon AD, Oren E, Ben-Bassat Y. Cortical bone remodeling/tooth movement ratio during maxillary incisor retraction with tip versus torque movements. *Am J Orthod Dentofacial Orthop.* 1998;114(5):520-9.
22. Reitan K. Effects of force magnitude and direction of tooth movement on different alveolar bone types. *Angle Orthod.* 1964;34(4):244-55.
23. Reitan K. Influence of variation in bone type and character on tooth movement. *Eur Orthod Soc Tr.* 1963;39:137-54.
24. Chaitanya ASK, Reddy YM, Sreekanth C, Reddy BV, Kumar BL, Raj GKP. Orthodontic tooth movements and its effects on periodontium. *Int J Dent Med Res.* 2014;1(4):119-23.
25. Deng Y, Sun Y, Xu T. Evaluation of root resorption after comprehensive orthodontic treatment using cone beam computed tomography (CBCT): a meta-analysis. *BMC Oral Health.* 2018;18(1):1-14.
26. de Almeida MR, Marçal ASB, Fernandes TMF, Vasconcelos JB, de Almeida RR, Nanda R. A comparative study of the effect of the intrusion arch and straight wire mechanics on incisor root resorption: a randomized, controlled trial. *Angle Orthod.* 2018;88(1):20-6.
27. Sun Q, Lu W, Zhang Y, Peng L, Chen S, Han B. Morphological changes of the anterior alveolar bone due to retraction of anterior teeth: a retrospective study. *Head Face Med.* 2021;17(1):1-12.
28. Björk A, Skieller V. Growth of the maxilla in three dimensions as revealed radiographically by the implant method. *Br J Orthod.* 1977;4(2):53-64.