

การเปรียบเทียบพื้นที่ผิวรากฟันของผู้ป่วยไทยที่มีความสัมพันธ์ ของกระดูกขากรรไกรแบบที่ 1 (Class I) และ แบบที่ 2 (Class II) โดยใช้ภาพรังสีโคน빔คอมพิวเตอร์โทโมกราฟี

Comparison of Maxillary Root Surface Areas in Thai Patients with Class I and Class II Skeletal Patterns Using Cone-beam Computed Tomography

Suchada Limsiriwong¹, Wikanda Khemaleelaku², Supassara Sirabanchongkran², Patiyut Sriwilas³, Dhirawat Jotikasthira²
¹นักศึกษาระดับปริญญาเอก สาขาทันตกรรมจัดฟัน คณะทันตแพทยศาสตร์ มหาวิทยาลัยเชียงใหม่
²ภาควิชาทันตกรรมจัดฟันและทันตกรรมสำหรับเด็ก คณะทันตแพทยศาสตร์ มหาวิทยาลัยเชียงใหม่
³คณะแพทยศาสตร์ ศิริราชพยาบาล มหาวิทยาลัยมหิดล

Suchada Limsiriwong¹, Wikanda Khemaleelaku², Supassara Sirabanchongkran², Patiyut Sriwilas³, Dhirawat Jotikasthira²
¹Graduate student, Division of Orthodontics Dentistry, Faculty of Dentistry, Chiang Mai University
²Department of Orthodontics and Pediatric Dentistry, Faculty of Dentistry, Chiang Mai University
³Faculty of Medicine Siriraj Hospital, Mahidol University

ชม. ทันตสาร 2562; 40(1) : 57-66
CM Dent J 2019; 40(1) : 57-66

Received: 19 April, 2018
Revised: 30 May, 2018
Accepted: 5 June, 2018

บทคัดย่อ

วัตถุประสงค์: เพื่อเปรียบเทียบพื้นที่ผิวรากฟันของฟันแท้ในขากรรไกรบนในผู้ป่วยไทยที่มีรูปแบบความสัมพันธ์ของกระดูกขากรรไกรแบบที่ 1 (Class I) และแบบที่ 2 (Class II) โดยใช้ภาพรังสีโคน빔คอมพิวเตอร์โทโมกราฟี (Cone-beam computed tomography)

วัสดุและวิธีการ: คัดเลือกภาพภาพรังสีโคน빔คอมพิวเตอร์โทโมกราฟี ก่อนการจัดฟันของผู้ป่วยไทยที่มีรูปแบบความสัมพันธ์ของกระดูกขากรรไกรแบบที่ 1 และแบบที่ 2 จำนวน 30 คน ฟันในขากรรไกรบนจากฟันตัดซี่กลางถึงฟันกรามซี่ที่สองทั้งสองข้างถูกเลือกเพื่อระบุขอบเขตและ

Abstract

Purpose: To compare root surface areas of maxillary permanent teeth in Thai patients with Class I and Class II skeletal patterns using cone-beam computed tomography.

Materials and Methods: Pretreatment cone-beam computed tomography images of 30 Thai orthodontic patients with Class I and Class II skeletal patterns were selected. Maxillary teeth from central incisor to second molar on both sides were chosen for investigation with 3-D dental

Corresponding Author:

ธีระวัฒน์ โชติคเศกียร

ศาสตราจารย์, ภาควิชาทันตกรรมจัดฟันและทันตกรรมสำหรับเด็ก,
คณะทันตแพทยศาสตร์ มหาวิทยาลัยเชียงใหม่ 50200

Dhirawat Jotikasthira

Professor, Department of Orthodontics and Pediatric
Dentistry, Faculty of Dentistry, Chiang Mai University,
Chiang Mai 50200, Thailand
E-mail: dhirawat.j@gmail.com

สร้างโครงร่างของตัวฟันและรากฟันทั้ง 3 มิติ มีการระบุและทำเครื่องหมายบริเวณรอยต่อเคลือบฟันและเคลือบรากฟัน (cement-enamel junction) พื้นที่ที่อยู่ใต้รอยต่อเคลือบฟันและเคลือบรากฟันไปจนถึงปลายรากฟันจะถูกวัดเป็นพื้นที่ผิวรากฟัน ข้อมูลที่ได้ถูกนำไปวิเคราะห์ด้วยสถิติเชิงพรรณนา

ผลการศึกษา: พื้นที่ผิวรากฟันโดยเฉลี่ยของฟันแท้ในขากรรไกรบนแต่ละซี่จากฟันตัดซี่กลางถึงฟันกรามซี่ที่สองในผู้ป่วยที่มีความสัมพันธ์ของกระดูกขากรรไกรแบบที่ 1 เท่ากับ 208.51, 193.87, 275.54, 258.70, 233.35, 447.41 และ 386.26 ตารางมิลลิเมตรตามลำดับ และ 203.55, 191.16, 262.44, 236.47, 227.91, 408.38 และ 351.70 ตารางมิลลิเมตรตามลำดับในผู้ป่วยที่มีความสัมพันธ์ของกระดูกขากรรไกรแบบที่ 2

สรุป: จากภาพรังสีโคมพิมคอมพิวเตอร์โทโมกราฟีพื้นที่ผิวรากฟันของฟันกรามน้อยบนซี่ที่หนึ่ง ฟันกรามบนซี่ที่หนึ่ง และฟันกรามบนซี่ที่สอง ในผู้ป่วยที่มีความสัมพันธ์ของกระดูกขากรรไกรแบบที่ 2 มีค่าน้อยกว่าอย่างมีนัยสำคัญเมื่อเทียบกับกลุ่มที่มีความสัมพันธ์ของกระดูกขากรรไกรแบบที่ 1

คำสำคัญ: มนุษย์ รากฟัน โคนบีมคอมพิวเตอร์โทโมกราฟีขากรรไกรบน

crown and root construction. The cemento-enamel junction was identified and labeled; the area apical to the cemento-enamel junction was measured as the root surface area. Descriptive statistical analyses were performed.

Results: Mean root surface areas of maxillary permanent teeth from central incisor to second molar in patients with Class I skeletal pattern were 208.51, 193.87, 275.54, 258.70, 233.35, 447.41 and 386.26 mm², respectively, and 203.55, 191.16, 262.44, 236.47, 227.91, 408.38 and 351.70 mm², respectively in those with Class II skeletal pattern. Root surface areas of first premolar, first molars and second molars in patients with Class II skeletal pattern were significantly smaller than those with Class I skeletal pattern.

Conclusions: Root surface areas of maxillary first premolars, first molars and second molars in patients with Class II skeletal pattern were smaller than those with Class I skeletal pattern.

Keywords: humans, tooth root, cone-beam computed tomography, maxilla

Introduction

Since the forces required for orthodontic tooth movement are related to root surface area,⁽¹⁾ optimum force magnitude to initiate orthodontic movement for a particular tooth should be individualized based on the root surface area. Especially for distal movement of maxillary teeth in patients with a large overjet or crowding in the anterior region, this mechanical variation is quite common in patients with Class I or Class II skeletal patterns, but the suggested or proper orthodontic force for distalization was not clear. Because many studies have found some differences between patients with Class I and those with Class II skeletal patterns, for

example, differences in mastication force or bite force,⁽²⁾ interradicular distance or buccal cortical bone thickness,^(3,4) there might also be some differences in root surface area. Several studies have reported root surface areas in subjects from various races and age groups;⁽⁵⁻¹⁴⁾ however, different root surface measuring methods were utilized in those studies and no skeletal classifications included. Since root surface area in Thai subjects has not yet been investigated, and because the combination of cone beam computed tomography (CBCT) and computer software programs should lead to both increased accuracy of measurement and a conservative way to assess data regarding living patients, this study was

aimed to measure and compare the root surface area of non-extracted, maxillary permanent teeth in Thai patients with Class I and those with Class II skeletal patterns.

Materials and Methods

This study was approved by the Human Experimentation Committee, Faculty of Dentistry, Chiang Mai University, Thailand (No.23/2558). Informed consent was obtained from all patients before CBCT images were acquired.

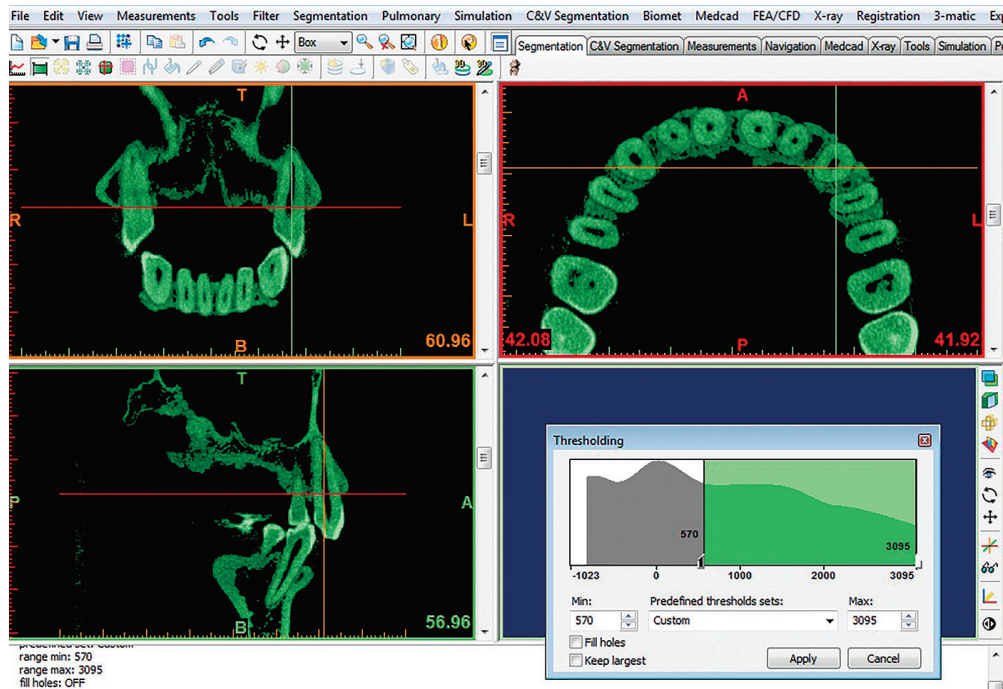
Pretreatment CBCT images of 15 Thai orthodontic patients with Class I skeletal relationship ($ANB = 2 \pm 2$ degrees), and 15 with Class II skeletal relationship ($ANB > 4$ degrees) were selected. Sample size was calculated with difference between two independent means (two groups), an effect size of 0.95 at a significance level of $\alpha = 0.05$ and power of test of $1 - \beta = 0.8$, using G*Power⁽¹⁵⁾. The calculation yielded at least 15 samples for each group. The inclusion criteria included: 1) patients had all permanent teeth with complete root formation (except for the third molars), 2) patient's age was between 15 and 25 years, 3) teeth should have no deviation in form, 4) no history of previous orthodontic treatment, 5) no severe craniofacial disorders or any systemic disease, and 6) no radiographic sign of periapical or bone lesions. All CBCT images were obtained using a Promax 3D (Planmeca OY, Helsinki, Finland) CBCT machine, at 8 cm x 8 cm field of view, 84 kVp, and 9 mA, and voxel size of 0.16 mm, in the Division of Oral and Maxillofacial Radiology, Department of Oral Biology and Diagnostic Sciences, Faculty of Dentistry, Chiang Mai University. Each patient was positioned in the radiographic device, sitting and keeping the occlusal plane horizontal.

Each CBCT image was converted from a Digital Imaging and Communications in Medicine (DICOM) file to a Stereolithography (STL) file,

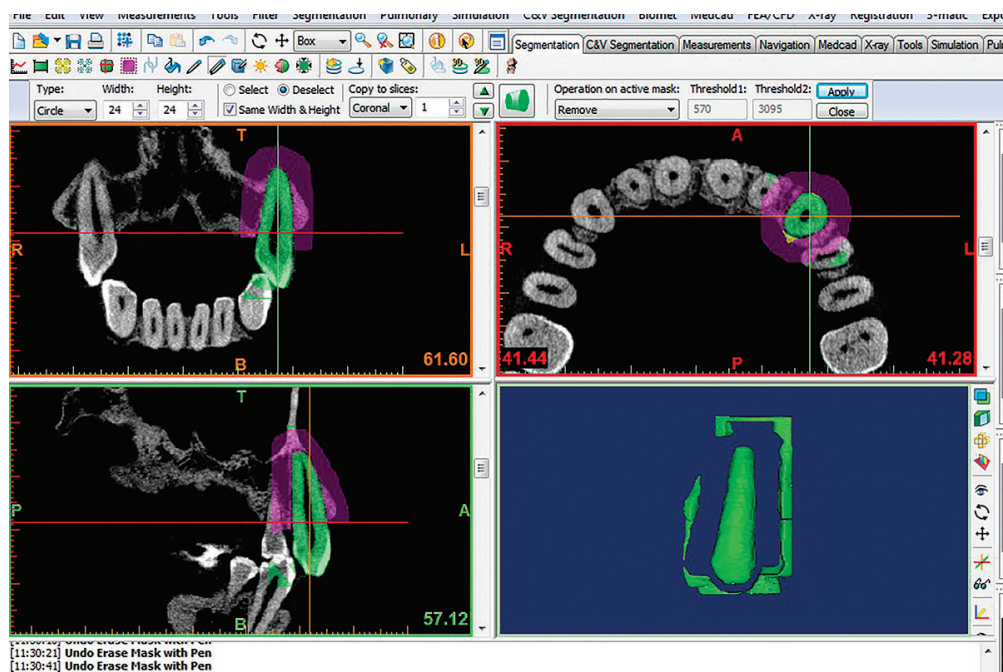
using the Mimics software (version 15.01, Materialise, Leuven, Belgium) with functions that allow for the production of 3-D models. All crowns and roots of the maxillary teeth were isolated from the rest of the skull using thresholding and region growing tools (Figure 1). By thresholding, the image is overlaid with a mask that contains only those pixels of the image with a value equal to or higher than the thresholding value. The pixels of the supporting structures with a similar value to the thresholding value were removed manually in each slice in all (sagittal, coronal and axial) views (Figure 2). Once each tooth was isolated, intentional extension spine markings were added manually to clearly identify the CEJ after 3-D dental reconstruction (Figure 3). Each 3-D dental reconstruction was saved and then exported to 3-Matic software (version 7.01, Materialise, Leuven, Belgium). Before root surface area measurement, the CEJ of each tooth was labeled, following the intentional extension spine marking in the 3-D dental reconstruction. The surface area apical to the CEJ was measured as the root surface area of each tooth (Figure 4). These methods were repeated twice for each selected tooth; then the average root surface area of each tooth was used.

Statistical analysis

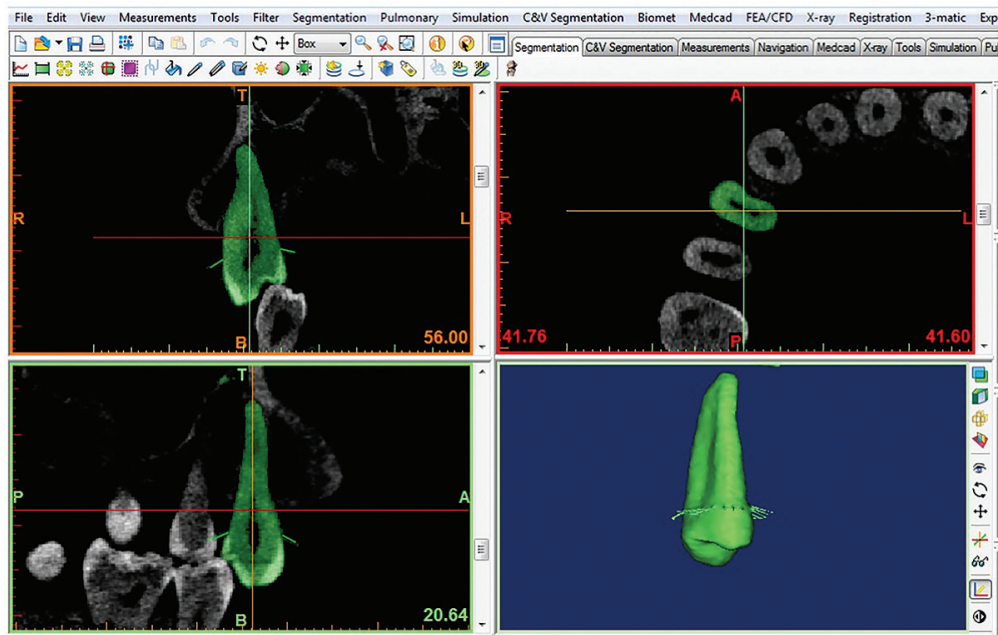
The errors of the method and the reliability of the measurements were tested. The CBCT images of 30 maxillary jaws were randomly selected and re-measured by the same examiner after a four-week interval. The intra-examiner variation was assessed using an intraclass correlation coefficient (ICC). There was excellent reliability between the first and the second root surface area measurements by the same examiner as calculated by intraclass correlation coefficient ($ICC > 0.98$). The data were analyzed by descriptive analysis to obtain the mean and standard deviation of all measurements using SPSS version 16.0 for Windows (SPSS Inc., Chicago, Illinois,



รูปที่ 1 การจับภาพหน้าจอแสดงการเลือกขอบเขตพื้นที่ทำงานสำหรับตัวฟันและรากฟันในขากรรไกรบนทั้งหมด
Figure 1 Screen capture showing the threshold selected for the working area to present crowns and roots of all maxillary teeth.

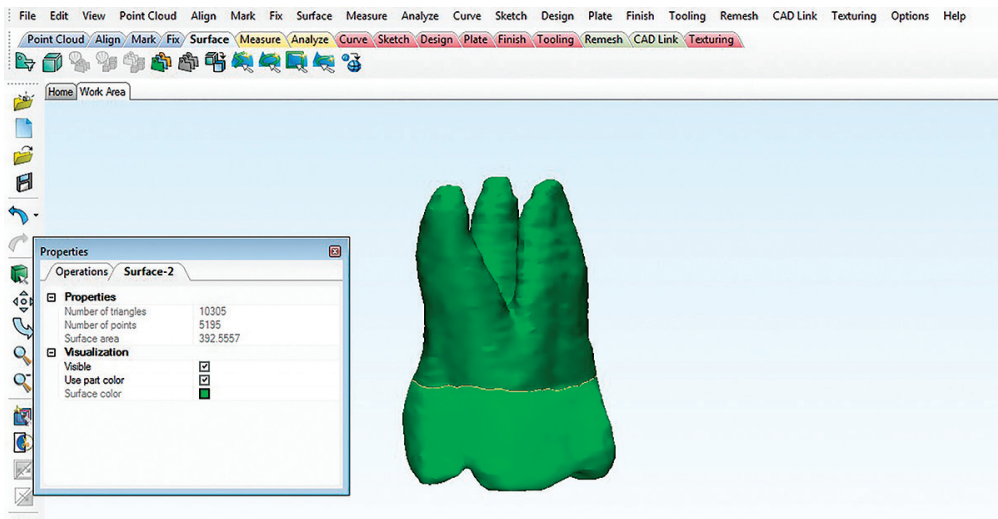


รูปที่ 2 การจับภาพหน้าจอที่ระดับความสูงหนึ่ง แสดงการเลือกกลบกระดูกรองรับรากฟันบริเวณฟันเขี้ยวบนด้านซ้าย (ตัวอย่าง) : ในมุมมองระนาบแบ่งฟันหน้าหลัง, ระนาบแบ่งฟันข้างขวา และระนาบแบ่งฟันบนล่าง
Figure 2 Screen capture of one slice showing the supporting structures around the left maxillary canine (for example) manually removed: in sagittal, coronal and axial views.



รูปที่ 3 การจับภาพหน้าจอแสดงการทำสัญลักษณ์บริเวณรอยต่อเคลือบฟันและเคลือบรากฟัน (เส้นสีเขียว) ในมุมมองระนาบแบ่งฟันหน้าหลังและระนาบแบ่งฟันข้างขวา เพื่อง่ายต่อการระบุตำแหน่งของรอยต่อเคลือบฟันและเคลือบรากฟันหลังการสร้างภาพฟันสามมิติ

Figure 3 Screen capture showing intentional extension spine markings (green lines) at the CEJ in both sagittal and coronal views for clearly identifying the CEJ after 3-D dental reconstruction.



รูปที่ 4 การจับภาพหน้าจอแสดงพื้นที่ผิวรากฟันกรามบนซี่ที่หนึ่ง วัดโดยโปรแกรม 3-Matic (พื้นที่สีเขียวเข้มจากบริเวณรอยต่อเคลือบฟันและเคลือบรากฟันถึงปลายรากฟัน)

Figure 4 Screen capture showing the root surface area of maxillary first molar measured by the 3-Matic program (dark green area from CEJ to root apex).

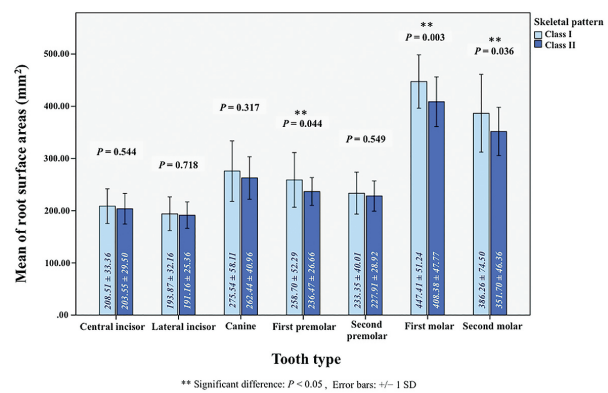
USA). Results were considered statistically significant at $p < 0.05$. The unpaired t-test was used to analyze differences between measurements on the right and the left sides. No significant difference was found, so the measurements were pooled for analysis. An independent t-test was used to compare the mean values of all collected measurements from patients with Class I and Class II skeletal patterns.

Results

Each CBCT image included seven maxillary permanent teeth on both sides; therefore, the number of samples included 30 samples per tooth type per group ($n=30/\text{tooth}/\text{skeletal classification}$). The mean age of the patients with Class I skeletal pattern (12 females and 3 males) was 20.12 (15.67-28.17) years, and that of the patients with Class II skeletal pattern (10 females and 5 males) was 19.98 (15.58-27.92) years (Table 1).

The mean and standard deviation of root surface area of the maxillary teeth in patients with Class I and Class II skeletal patterns are presented in Figure 5. The mean root surface area of maxillary teeth ranged from 191.16 to 447.41 mm^2 . The greatest root surface area was found in the maxillary first molars in patients with Class I ($447.41 \pm 51.24 \text{ mm}^2$) and Class II ($408.38 \pm 47.77 \text{ mm}^2$) skeletal patterns. The smallest root surface area was found in the maxillary

lateral incisors in patients with Class I ($193.87 \pm 32.16 \text{ mm}^2$) and Class II ($191.16 \pm 25.36 \text{ mm}^2$) skeletal patterns. The maxillary root surface areas in Class II skeletal pattern were smaller than those in Class I skeletal pattern in all tooth types, but only those of first premolars, first molars and second molars in Class II skeletal pattern were significantly smaller than those in Class I skeletal pattern ($P=0.044$, $P=0.003$, $P=0.036$, respectively) (Figure 5).



รูปที่ 5 แสดงค่าเฉลี่ยของพื้นที่ผิวรากฟันของแต่ละซี่ โดยใช้ข้อมูลจากภาพรังสีโคนบีมคอมพิวเตอร์โทโมกราฟี ในผู้ป่วยที่มีความสัมพันธ์ของกระดูกขากรรไกรแบบที่ 1 และในผู้ป่วยที่มีความสัมพันธ์ของกระดูกขากรรไกรแบบที่ 2

Figure 5 Mean root surface areas of each maxillary tooth type measured from Cone-beam computed tomography images in patients with Class I, and in those with Class II skeletal patterns.

ตารางที่ 1 แสดงอายุ (ปี) แจกแจงโดยความสัมพันธ์ของกระดูกขากรรไกร เพศ และจำนวนภาพรังสีโคนบีมคอมพิวเตอร์โทโมกราฟี (n)

Table 1 Ages (years) distributed by skeletal pattern, sex, and number of samples (n) for Cone-beam computed tomography image selection.

Skeletal pattern	Sex	n	Age (years)			
			Minimum	Maximum	Mean	Standard deviation
Class I	Female	12	15.67	28.17	20.13	3.38
	Male	3	15.67	22.33	20.08	3.82
Class II	Female	10	15.58	26.17	20.18	3.73
	Male	5	16.17	27.92	19.57	4.88

Discussion

The CBCT images of the root surface areas in both Class I and Class II skeletal patterns indicated that, the first molars showed the largest root surface areas, and the lateral incisors the smallest. Our results concur with those reported by previous studies (Table 2).^(5,6,9,12)

Although the root surface areas of all maxillary teeth in Class II skeletal pattern were smaller than those in Class I skeletal pattern, only the root surface areas of first premolars, first molars, and second molars showed significant differences. Araújo *et al.*⁽¹⁾ suggested that lower bite force might be found in subjects with Class II skeletal pattern than in Class I skeletal pattern. This lower bite force might result from the compensation of tooth inclination and angulation for Class II skeletal discrepancies, and this compensation might cause improper occlusal contact.⁽¹⁶⁻¹⁸⁾ Other investigators⁽¹⁹⁻²¹⁾ have reported that lower bite force was associated with shorter root length and smaller root surface area, especially in posterior regions. Normal occlusal loading and function is responsible for normal development of alveolar bone, dental root and associated supporting structures. Occlusal hypofunction decreases alveolar bone mass, accelerates bone resorption, causes deficient root development and leads to atrophic changes in the periodontal ligament⁽²²⁻²⁴⁾ as reported

with short dental roots from incisors to premolars in patient with anterior open bite.⁽²⁵⁻²⁶⁾ In addition, the smaller root surface area in Class II skeletal pattern may be associated with the wider interradicular distances reported by Khumsarn *et al.*⁽³⁾ This association may need further investigation.

From the study by a group of Seon-Young Kim in 2013,⁽²⁷⁾ they reported that the dental root length of all tooth types are longer in male than female, So we tried to select the CBCT images of sample in most similar number of gender for each group as possible to reduce this influence factor.

Our CBCT measurement method was accurate and appropriate, especially for measuring non-extracted or vital teeth.⁽²⁸⁾ The measured teeth in this investigation were selected from the complete maxillary dentitions of 30 living subjects. So, the inclusion criteria of the samples were greatly improved from those of the previous root surface area investigations,^(5,6,9,12) in which extracted teeth were selected from different subjects. Such selections had a chance for bias.

Conclusions

The root surface areas measured from CBCT images in Class II skeletal pattern were smaller than those in Class I skeletal pattern in all tooth types, especially those of first premolars, first molars and

ตารางที่ 2 แสดงค่าพื้นที่ผิวรากฟันที่วัดได้จากการศึกษานี้และการศึกษาอื่น ๆ^(5,6,9,12)

Table 2 Maxillary root surface areas of this study and others.^(5,6,9,12)

Research study Tooth type	This study (2016)		Yamamoto <i>et al.</i> (2006)	Hujoel <i>et al.</i> (1994)	Tylman <i>et al.</i> (1960)	Boyd <i>et al.</i> (1958)
	Class I	Class II				
Central incisor	208.5±33.4	203.6±29.5	200.7±25.9	200	139	204.5
Lateral incisor	193.9±32.2	191.2±25.4	202.9±25.2	180	112	177.3
Canine	275.5±58.1	262.4±41.0	291.9±38.8	290	204	266.5
First premolar	258.7±52.3	236.5±26.7	249.4±37.3	250	149	219.7
Second premolar	233.4±40.0	227.9±28.9	232.9±32.0	230	140	216.7
First molar	447.4±51.2	408.4±47.8	467.7±61.6	475	335	454.8
Second molar	386.3±74.5	351.7±46.3	368.4±52.4	405	272	416.9

second molars in Class II skeletal pattern, which were significantly smaller. These findings suggest that the sagittal skeletal pattern may be the principle factor in determining the root surface area, especially in the posterior region. So, the root surface areas might be associated with the sagittal skeletal pattern. The association between the vertical skeletal pattern and the root surface areas should also be further investigated. The reported mean root surface area may serve as a baseline for future study and for clinical decisions, such as identifying the amount of force required for orthodontic movement for each patient or for each skeletal type.

Acknowledgements

We would like to express our gratitude to the Department of Radiology, Faculty of Medicine Siriraj Hospital, Mahidol University, for simulation software support and guidance throughout the study, to members of the Department of Orthodontics and Pediatric Dentistry, and Faculty of Dentistry, Chiang Mai University for their support and suggestions, and to Dr. M. Kevin O Carroll, Professor Emeritus of the University of Mississippi, School of Dentistry, and Faculty Consultant at Chiang Mai University, Faculty of Dentistry, for his assistance in editing the manuscript.

References

1. Crabb JJ, Wilson HJ. A method of measuring root areas of extracted teeth. *J Dent* 1974; 2: 171-174.
2. Araújo SCCS, Vieira MM, Gasparotto CA, Bommarito S. Bite force analysis in different types of angle malocclusions. *Revista CEFAC* 2014; 16: 1567-1578. <https://dx.doi.org/10.1590/1982-021620145113>
3. Khumsarn N, Patanaporn V, Janhom A, Jotikas-thira D. Comparison of Interradicular Distances and Cortical Bone Thickness in Thai Patients with Class I and Class II Skeletal Patterns Using Cone-Beam Computed Tomography. *Imaging Sci Dent* 2016; 46: 117-125.
4. Chaimanee P, Suzuki B, Suzuki EY. "Safe zones" for minis-crew implant placement in different dentoskeletal patterns. *Angle Orthod* 2011; 81: 397-403.
5. Boyd JD, Sims RW Jr, Osgood DR, Blum AS. Photographic versus autoradiographic portrayal of dental structure. *Int J Appl Radiat Isot* 1958; 3: 8-12.
6. Tylman SD, Tylman SG. *Theory and practice of crown and bridge prosthodontics*. 4th ed. St. Louis C. V: Mosby; 1960: 161-162
7. Jepsen A. Root surface measurement and a method for x-ray determination of root surface area. *Acta Odontol Scand* 1963; 21: 35-46.
8. Nicholls JI, Daly CH, Kydd WL. Root surface measurement using a digital computer. *J Dent Res* 1974; 53: 1338-1341.
9. Hujoel PP. A meta-analysis of normal ranges for root surface areas of the permanent dentition. *J Clin Periodontol* 1994; 21: 225-229.
10. Mowry JK, Ching MG, Orjansen MD, Cobb CM, Friesen LR, MacNeill SR, et al. Root surface area of the mandibular cuspid and bicuspid. *J Periodontol* 2002; 73: 1095-1100.
11. Pan JH, Chen SK, Lin CH, Leu LC, Chen CM, Jeng JY. Estimation of single-root surface area from true thickness data and from thickness derived from digital dental radiography. *Dento-maxillofac Radiol* 2004; 33: 312-317.
12. Yamamoto T, Kinoshita Y, Tsuneishi M, Takizawa H, Umemura O, Watanabe T. Estimation of the remaining periodontal ligament from attachment-level measurements. *J Clin Periodontol* 2006; 33: 221-225.

13. Li W, Chen F, Zhang F, et al. Volumetric measurement of root resorption following molar mini-screw implant intrusion using cone beam computed tomography. *PLoS One* 2013; 8: e60962.
14. Gu Y, Tang Y, Zhu Q, Feng X. Measurement of root surface area of permanent teeth with root variations in a Chinese population-A micro-CT analysis. *Arch Oral Biol* 2016; 63: 75-81.
15. Faul F, Erdfelder E, Lang AG, Buchner A. G*Power 3: A Flexible Statistical Power Analysis Program for the Social, Behavioral, and Biomedical Sciences. *Beh Res Methods* 2007; 39: 175-191.
16. Braun S, Bantleon HP, Hnat WP, Freudenthaler JW, Marcote MR, Johnson BE. A study of bite force, part 1: Relationship to various physical characteristics. *Angle Orthod* 1995; 65: 367-372.
17. Bakke M, Holm B, Jensen BL, Michler L, Moller E. Unilateral, isometric bite force in 8-68-year-old women and men related to occlusal factors. *Scand J Dent Res* 1990; 98: 149-158.
18. Andrews LF. The six keys to normal occlusion. *Am J Orthod* 1972; 62: 296-309.
19. Spencer MA. Tooth-root form and function in platyrrhine seed-eaters. *Am J Phys Anthropol* 2003; 122: 325-335.
20. Kupczik K, Olejniczak AJ, Skinner MM, Hublin J. Molar crown and root size relationship in anthropoid primates. *Front Oral Biol* 2009; 13: 16-22.
21. Lucus L. *Variation in dental morphology and bite force along the tooth row in anthropoids*. Doctor of Philosophy, Arizona State University, August 2012; 243-260.
22. Enokida M, Kaneko S, Yanagishita M, Soma K. Influence of occlusal stimuli on the remodelling of alveolar bone in a rat hypofunction-recovery model. *J Oral Biosci* 2005; 47: 321-334.
23. Hayashi Y, Iida J, Warita H, Soma K. Effects of occlusal hypofunction on the microvasculature and endothelin expression in the periodontal ligaments of rat molars. *Orthod Waves* 2001; 60: 373-380.
24. Tanaka A, Iida J, Soma K. Effect of hypofunction on the microvasculature in the periodontal ligament of the rat molar. *Orthod Waves* 1998; 57: 180-188.
25. Karavade R, Kalia A, Nene S, Khandekar S, Patil V. Comparison of root-crown lengths and occlusal contacts in patients with class-III skeletal relationship, anterior open-bite and high mandibular plane angle. *Int J Dent Med Spec* 2015; 2: 7-13.
26. Uehara S, Maeda A, Tomonari H, Miyawaki S. Relationships between the root-crown ratio and the loss of occlusal contact and high mandibular plane angle in patients with open bite. *Angle Orthod* 2012; 83: 36-42.
27. Kim SY, Lim SH, Gang SN, Kim HJ. Crown and root lengths of incisors, canines, and premolars measured by cone-beam computed tomography in patients with malocclusions. *Korean J Orthod* 2013; 43: 271-278.
28. Tasanapanont J, Apisariyakul J, Wattanachai T, Sriwilas P, Midtbø M, Jotikasthira D. Comparison of 2 root surface area measurement methods: 3-dimensional laser scanning and cone-beam computed tomography. *Imaging Sci Dent* 2017; 47: 117-122.